

Overview of the Management of Nasal Septal Hematoma/Abscess at Golden Cross Infirmary Private Facility in Lagos, Nigeria

Waheed Atilade Adegbiiji¹, Shuaib Kayode Aremu^{2*}, AbdulAkeem A. Aluko³
and Olawale Olubi⁴

¹Department of ENT, Ekiti State University Teaching Hospital, Ado Ekiti, Nigeria.

²Department of ENT, Federal Teaching Hospital Ido-Ekiti, Afe-Babalola University, Ekiti State, Ado-Ekiti, Nigeria.

³Department of ENT, Bayero University Kano State, Aminu Kano Teaching Hospital, Kano State, Nigeria.

⁴Department of ENT, Lagos State University Teaching Hospital, Lagos State, Nigeria.

Authors' contributions

This work was carried out in collaboration between all authors. Author WAA designed the study, performed the statistical analysis, wrote the protocol and wrote the first draft of the manuscript. Authors SKA and AAA managed the analyses of the study. Author OO managed the literature searches. All authors read and approved the final manuscript.

Article Information

DOI: 10.9734/AJMPCP/2018/43403

Editor(s):

- (1) Dr. Kumud Kumar Kafle, Department of Clinical Pharmacology, Tribhuvan University, Kathmandu, Nepal.
(2) Dr. B. Venkata Raman, Department of Biotechnology, Centre for Biomedical Research, K L University, Vaddeswaram, India.

Reviewers:

- (1) Ajinkya Kelkar, India.
(2) Kyung-Su Kim, College of Medicine, Yonsei University, South Korea.
(3) Ramesh Gurunathan, General Surgery Sunway Medical Center, Malaysia.
(4) Jadi Lingaiah, Kaloji Narayana Rao University, India.

Complete Peer review History: <http://www.sciencedomain.org/review-history/26248>

Original Research Article

Received 30th June 2018
Accepted 3rd September 2018
Published 15th September 2018

ABSTRACT

Background: Nasal septal abscess is an uncommon nasal disorder which was recently diagnosed and confirm to require meticulous and urgent management.

This study is aimed at determining the clinical presentation, diagnosis, and management of septal abscess at Golden cross infirmary center in Lagos.

Method: This research is a prospective hospital-based study about consecutive patients diagnosed

with nasal septal abscess over a five-year period at the Golden cross infirmary private facility in Lagos, Nigeria. Consented patients were enrolled in the study, and data obtained were collated and analyzed using SPSS version 18.

Results: Forty-seven (47) patients comprising 32 males (68.1% of total patients) and 15 females (31.9% of total patients) were enrolled in the study which is a male to female ratio of 2:1.

The peak age groups of incidences were ≤ 10 and 41-50 years age group.

Patients duration of illness at presentation were; 14 patients (29.8% of total patients) with illness within a week, 4 patients (8.5% of total patients) with illness within 2 weeks, and 29 patients (61.7% of total patients) with illness within 3 weeks. Sources of referral were 19 patients (40.4% of total patients) from a general practitioner and 24 patients (51.1% of total patients) from a family physician.

45 patients (95.7% of total patients) who form the majority in our research were from the Ear, Nose, and Throat (ENT) outpatient clinic, while 1 patient (2.1% of total patients) was from the casualty center (accident and emergency), and 1 patient (2.1% of total patients) from the hospital wards.

Clinical features at presentation were 47 patients (100% of total patients) with nasal blockage, 43 patients (91.5% of total patients) with difficulty breathing, 38 patients (80.9% of total patients) with nasal pain, 45 patients (95.7% of total patients) with rhinorrhea, 26 patients (55.3% of total patients) with mouth breathing, 19 patients (40.4% of total patients) with Snoring issues, 28 patients (59.6% of total patients) with headache, 12 patients (25.5% of total patients) with poor appetite and 8 patients (17.0% of total patients) with fever.

Hematoma/abscess was bilateral in 43 patients (91.5% of total patients). Needle aspiration of the nasal septum confirmed hematoma in 4 patients (8.5% of total patients), and abscess in 43 patients (91.5% of total patients). Aspirates microscopy, culture, and sensitivity tests were negative in 7 patients (14.9% of total patients) with growth of *Staphylococcus aureus* in 23 patients (48.9% of total patients), *Streptococcus* spp in 15 patients (31.9% of total patients), and *Hemophilium influenza* in 2 patients (4.3% of total patients).

Implicated aetiological factors were complicated acute rhinosinusitis in 31 patients (66.0% of total patients), trauma in 9 patients (19.1% of total patients), furunculosis/vestibulitis in 5 patients (10.6% of total patients), and idiopathic in 2 patients (4.3% of total patients).

All our patients had a combination of surgery (incision and drainage with drains), antibiotics, analgesic, and daily dressing. Complications recorded were; recurrence with 3 patients (6.4% of total patients), septal edema with 37 patients (78.7% of total patients), and facial cellulitis with 6 patients (12.8% of total patients).

Conclusion: Nasal septal hematoma/abscess are uncommon among the patients as acute sinonasal infection and trauma were identified as the main aetiological factors. A prolonged nasal obstruction, and not responding to nasal decongestant is a major pointer to early diagnosis as immediate surgical intervention was needed to prevent avoidable complications.

Keywords: Nasal septal abscess; septal hematoma; incision and drainage; rhinosinusitis; culture and sensitivity.

1. INTRODUCTION

The nose is a special sensory organ of the olfactory. Occupying the middle third of the face and been the most prominent facial structure makes it prone to most facial injuries [1]. The nasal septum is the midline bone and cartilage structure within the nose that separates the nasal cavity into two nostrils.

Nasal septal hematoma and abscess is defined as blood or pus collections between the bone or cartilaginous septum and the mucoperiosteum or mucoperichondrium [2]. Nasal septal hematoma/abscess is not a

common disorder as the prevalence isn't well established [3,2].

The awareness level of nasal septal hematoma/abscess has increased over the years across different centers. and it is important to examine the nasal septum of all individuals who have suffered trauma, and also examine nasal septum of individuals during the conduct of nasal clinical, and radiological examination [4,5]. There is gender predisposition to nasal injuries and septal hematoma/abscess as there was a predominance of male patients to septal hematoma/abscess. There are different aetiological causes of nasal septal hematoma/

abscess as most studies believe the common causes to be injuries from surgery, domestic assault, industrial, sporting activities, and accidents.

Other causes are infections of facial structures such as a dental abscess, ethmoid and sphenoid sinusitis, with nasal furunculosis [6,7,8]. However, in clinical diagnosis, the absence of antecedent facial or nasal trauma would prompt the possibility of another infection like nasal septal infection. The pathophysiology of nasal septal hematoma subsequent to nasal injury is poorly understood as there are mechanical forces which when in contact with the cartilage results in rupture to the vessels of the mucoperichondrium [9,10,11]. When there is an associated cartilage fracture, the blood vessel can be dissected through the fracture line and cause a bilateral hematoma. Accumulated hematoma expands and mechanically obstructs the vascular supply of the nasal cartilage, leading to avascular necrosis, induced by pressure within three to four days. The accumulated hematoma and necrotic tissue are good culture media for bacteria such as *Staphylococcus* that colonizes the nasal mucosa with resultant formation of an abscess. The common clinical manifestations at diagnosis are nasal obstruction, mouth breathing, nasal pain, local fluctuation, deformed nose, tender on palpation and reddish edema of septal mucosa [12]. Test aspirate may produce blood in hematoma or pus in an abscess.

Aspirate from nasal septum must be investigated as Microscopic culture and sensitivity usually showed offending organisms. Commonly isolated organisms are *Staphylococcus aureus*, *Staphylococcus viridans*, *Enterococcus faecalis*, *Streptococcus pyogenes*, *Streptococcus pneumoniae* and *Hemophilus influenza* [13]. Anaerobes and coliform microorganisms are less commonly isolated as fungal agents and has been implicated in immune compromised individuals. Further investigation includes a computerized tomography scan in suspected cases of intracranial complications.

Nasal septal hematoma/abscess is associated with cosmetic complication such as septal edema, facial cellulitis, osteocartilaginous necrosis and saddle nose [14,15]. Intracranial complications are due to the cranial extension of the diseases which includes subarachnoid empyema, meningitis, and cerebral abscess. Routes of intracranial extension are vascular (venous or lymphatic), fracture lines, suture lines,

surgical wound, and direct bone erosion by the diseases.

Nasal septal hematoma/abscess are treated using both surgical and medical approaches. Because of the paucity of literature on the nasal septal hematoma/abscess and its management in Nigeria, this study is aimed at determining the septal hematoma/abscess etiology, clinical features, complications, and management using the Golden cross infirmary private facility in Lagos, Nigeria.

2. MATERIALS AND METHODS OF RESEARCH

This research is a prospective hospital-based study of patients diagnosed with nasal septal abscess. All patients diagnosed with nasal septal abscess at the Golden-cross infirmary center, Lagos were enrolled in the study which was carried out over 5 years (January 2011 to December 2016).

Ethical clearance was obtained from the ethical committee of the hospital, and informed consent was obtained from patients/guardian/parents before patients were enrolled in the study, and consented patients were prospectively studied.

Interviewer-assisted questionnaire were given to the patients to obtain their detailed bio-data. Detailed otorhinolaryngological history, possible aetiological causes, predisposing factors, and past medical, surgical, family and social history were taken from the patient/guardian/parents. General physical and systemic examination was also performed and a thorough nose, ear, throat, head, and neck examination were conducted and documented. The thorough rhinological examination included anterior rhinoscopy, nasal cavity, and nasal septal examination. An aseptic needle aspiration of the nasal septum was performed, as the aspirates were examined and sent for microscopy, culture, and sensitivity test.

All the patients were educated based on the findings and the line of management of the nasal septal hematoma/abscess, as they were booked for incision and drainage. The procedure was performed under local or general anesthesia depending on the patient clinical status. Under local or general anesthesia, a vertical incision was made over the point of maximum fluctuance. The abscess loculi were broken and the septal cavity was irrigated with 0.9% saline solution and packed with Vaseline gauze, impregnated with gentamicin cream. Analgesic and broad-

spectrum antibiotics were prescribed and adjusted with the result of aspirate culture and sensitivity. Depending on the patient postoperative state, the patients were either treated as a day case or admitted. Participants were followed up (enrolled) in the Ear, Nose, and Throat Clinic (ENT Clinic) for a possible outcome and complications.

All data obtained were collated, analyzed, and documented using SPSS version 18.

3. RESULTS

There were 47 consented participants (patients) which comprise 32 males (68.1% of total patients) and 15 females (31.9% of total patients). This form a male to female ratio of 2:1. Table 1 shows the age distribution of the study population. The peak age group incidence was ≤10 years age group and 41-50 years age group.

Duration of illness before the presentation was: 4 patients (8.5% of total patients) with illness at 1 week, 14 patients (29.8% of total patients) with illness at 2weeks, and 29 patients (61.7% of total patients) with illness at 3weeks. This is illustrated in Fig. 1.

Sources of referral of patients with nasal septal abscess were; The Ear, Nose, and Throat (ENT) department with 43 patients (91.5% of total patients), a general practitioner with 1 patient (2.1% of total patients), and casualty officer with 3 patients (6.4% of total patients).

Table 1. Age group distribution of patients with nasal septal hematoma/abscess

Age group	Number of participants	Percentage (%)
≤10	11	23.4
11-20	8	17.2
21-30	5	10.6
31-40	6	12.8
41-50	14	29.8
≥51	3	6.4
Total	47	100

Majority of the patients were from the otorhinolaryngological outpatient clinic while a minority was from the emergency ward. These were: ENT outpatient clinic were 45 patients (95.7% of total patients), casualty unit (accident and emergency) with 1 patient (2.1% of total patients), and hospital wards with 1 patient (2.1% of total patients) as shown in Fig. 2.

Table 2 shows the clinical features of the patients at presentation with 47 patients (100% of total patients) with nasal blockage, 43 patients (91.5% of total patients) with difficulty breathing, 38 patients (80.9% of total patients) with nasal pain, 45 patients (95.7% of total patients) with rhinorrhea, 26 patients (55.3% of total patients) with mouth breathing, 19 patients (40.4% of total patients) with snoring issues, 28 patients (59.6% of total patients) with headache, 12 patients (25.5% of total patients) with poor appetite, and 8 patients (17.0% of total patients) with fever.

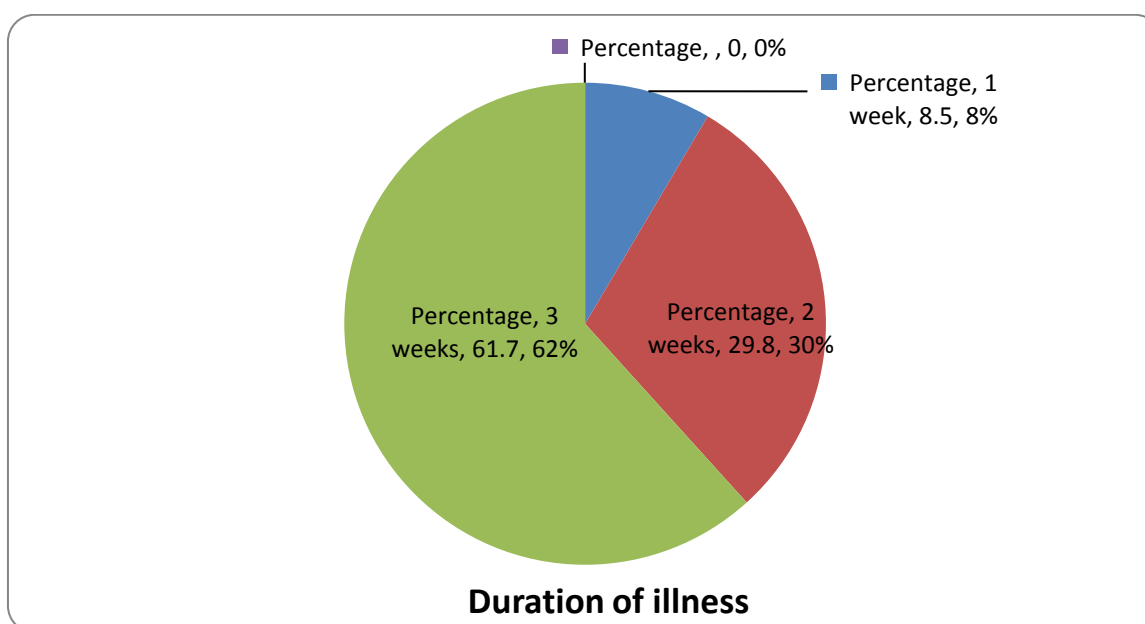


Fig. 1. Duration of illness

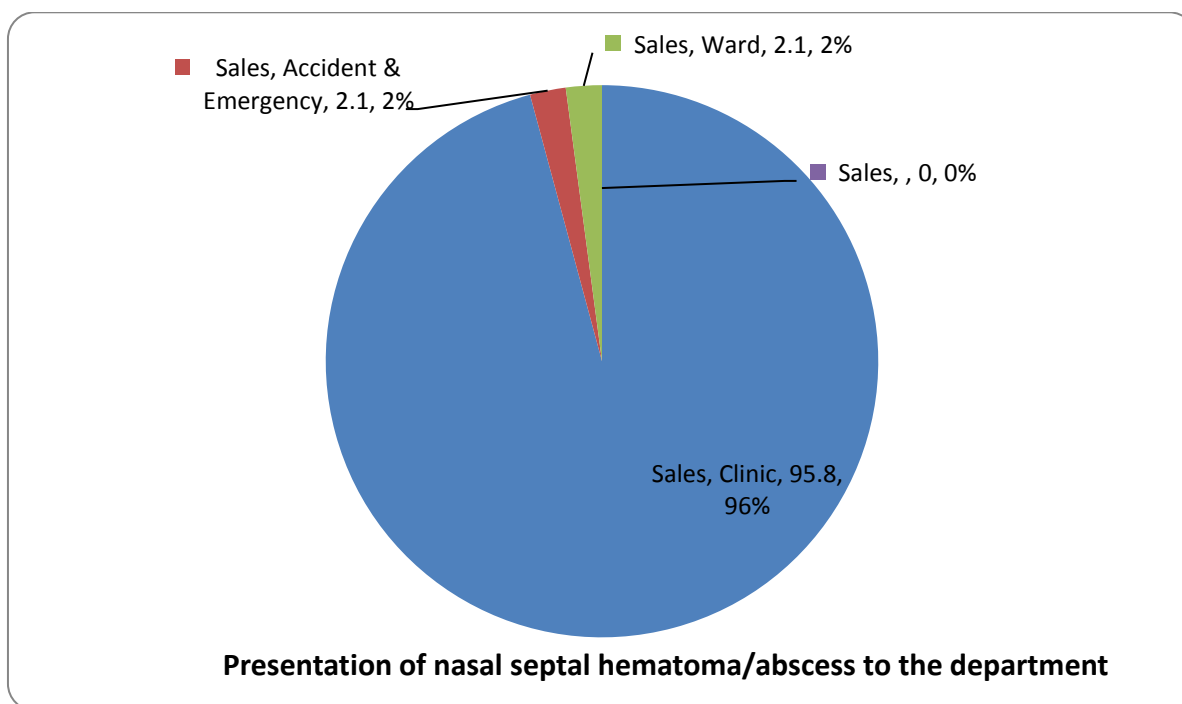


Fig. 2. Presentation of nasal septal hematoma/abscess to the department

Fig. 3 shows the major cause to be acute rhinosinusitis.

The hematoma/abscess cause was bilateral in 43 patients (91.5% of total patients), 3 patients (6.4% of total patients) in the right, and 1 patient (2.1% of total patients) in the left side of the nasal septum as illustrated in Fig. 2.

Needle aspiration of the nasal septum confirmed hematoma in 4 patients (8.5% of total patients) and abscess in 43 patients (91.5% of total patients).

All the aspirates from the nasal septum were sent for microscopy, culture, and sensitivity tests. A negative culture was noticed in 7 patients (14.9% of total patients), and a positive culture was noticed in 40 patients (85.1% of total patients). The analysis showed 23 patients (48.9% of total patients) were with *Staphylococcus aureus*, 15 patients (31.9% of total patients) were with *Streptococcus* spp and 2 patients (4.3% of total patients) were with *Haemophilus influenzae*. This is shown in Table 3.

Detailed history on aetiological factors showed complicated acute rhinosinusitis in 31 patients (66.0% of total patients), while trauma in 9 patients (19.1% of total patients), furunculosis with vestibulitis in 5 patients (10.6%

of total patients), and idiopathic in 2 patients (4.3% of total patients). This is illustrated in Fig. 3.

Table 2. Clinical presentation of patients with nasal septal hematoma/abscess

Symptoms	Number of patients (n)	Percentage (%)
Nasal blockage	47	100
Difficulty breathing	43	91.5
Nasal pain	38	80.9
Rhinorrhea	45	95.7
Mouth breathing	26	55.3
Snoring	19	40.4
Headache	28	59.6
Poor appetite	12	25.5
Fever	8	17.0

Table 3. Isolated microorganisms from nasal septal hematoma/abscess

Microorganisms	Number (n)	Percentage (%)
<i>Staphylococcus aureus</i>	23	48.9
<i>Streptococcus</i>	15	31.9
<i>Haemophilus influenzae</i>	2	4.3
Nil growth	7	14.9

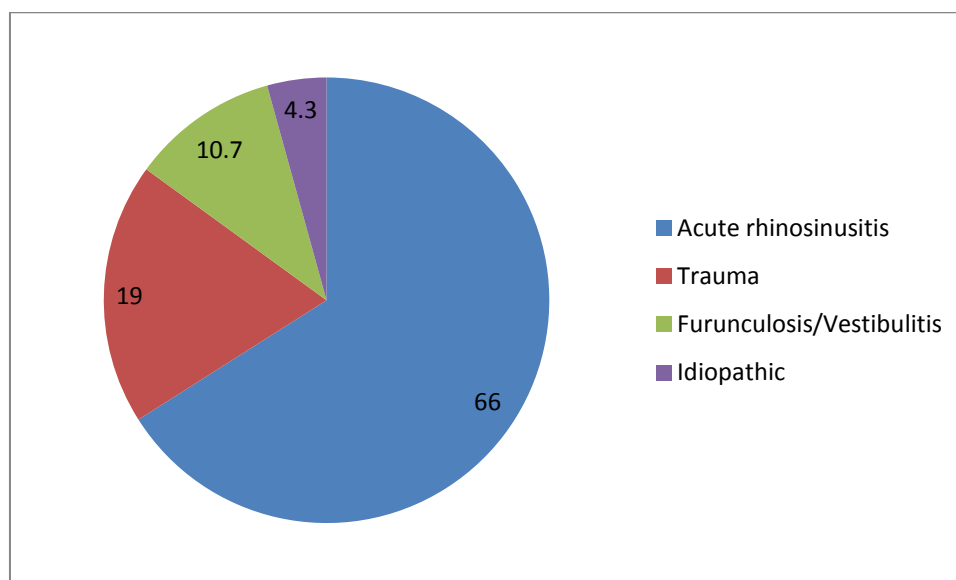


Fig. 3. Aetiology agent of nasal septal hematoma/abscess

Before presentation at our department, 44 patients (93.6% of total patients) had used some form of self-medication such as; 34 patients (72.3% of total patients) had used antibiotics, 11 patients (23.4% of total patients) had used decongestants, 38 patients (80.9% of total patients) had used analgesic and 42 patients (89.4% of total patients) had used vitamins.

All our patients had a combination of surgery (incision and drainage with drains), antibiotics, analgesic, and daily dressing until the abscess cavity was cleared. Incision and drainage were conducted under local anesthesia in 23 patients (48.9% of total patients), and general anesthesia in 24 patients (51.1% of total patients). Antibiotics were changed in 15 patients (31.9% of total patients) based on microscopic, culture and sensitivity result, as some patients responded to earlier treatment. The study population (all patients) was successfully treated and discharged. Participants were followed up as an outpatient over a 6 weeks period with no defaulters among all our participants. Recurrence was noticed in 3 patients (6.4% of total patients), and a further complication of nasal septal edema was observed in 37 patients (78.7% of total patients), and facial cellulitis was observed in 6 patients (12.8% of total patients).

4. DISCUSSION

Nasal septal hematoma/abscess are uncommon sinonasal disorders worldwide. This is evidenced with the diagnosis of 47 cases during this

research 5 years study at Golden cross infirmary center [12,13,14,16,15,17]. The rate of occurrence of nasal septal hematoma/abscess varies across studied communities [12]. In our study male participants (68.1% of total patients) were twice the number of females' participants in a ratio of M:F = 2:1, as earlier studies also showed a strong male predominance in hematoma/abscess of the nasal septum²⁰. Males are mostly involved in violence and accidents such as road traffic accidents, industrial and domestic accidents due to their role in the family compared to females. Males are also at greater risk of exposure to infection compared to females, hence they develop nasal septal hematoma/abscess unlike their female counterparts who are less prone to facial injuries.

Nasal septal hematoma/abscess affect all age groups, and in some findings, it is noted to be common in children [17]. Those findings believed the mucoperichondrium is not closely bound down to the cartilage in children compared to adults as mild trauma can easily lead to the collection of blood into the subperichondrial space from the torn blood vessels of the submucosal blood vessels. Our study showed the bimodal age group peaks at (≤ 10) and (41-50) age groups. This may be due to the findings of infection as a major cause of nasal septal hematoma/abscess while Trauma was a major aetiological agent in earlier studies [18,16,19]. In this study, the major aetiological agent was a sinonasal infection like complicated acute rhinosinusitis. Acute sinonasal infection leads to

an inflamed mucosa and fragile vascular dilatation. The act of nasal blowing and nasal squeezing, in nasal cleaning may lead to rupture of the inflamed mucosa microvessel among patient. This may either leads to epistaxis or subperichondrial hemorrhage. Subperichondrial hemorrhage causes a septal hematoma which when infected leads to septal abscess. In our research trauma is not seen as a major cause of nasal septal hematoma/abscess.

Patients with nasal septal hematoma/abscess usually were presented late to the otorhinolaryngologist, head and neck surgeons. The early stages characterized by hematoma, with traumatic etiology or cellulitis, and infective etiology were missed in most patients as an abscess could have been aborted with the simple drainage of hematoma or antibiotics and nasal septal cellulitis. That 61.7% of total patients (29 patients) who form the majority were in their third week of the disease could be the reason for the high percentage of patients [91.5% of total patients (43 patients)] with nasal septal abscess in this studied population, and 8.5% of total patients (4 patients) with hematoma in the same studied population.

With the majority of the patients [95.7% of total patients (45 patients) been present at our Ear, Nose, and Throat (ENT) clinic compared to 1 patient (2.1% of total patients) from the accident and emergency ward could be because of our participant were presented as cold cases. The patients were mostly stable at presentation. Further literature research showed few complicated cases at presentation to the otorhinolaryngologist, head and neck surgeon [20].

Patients and their managing doctors were not familiar with the symptoms of nasal septal diseases and its complications as sinonasal disease such as acute infective rhinosinusitis were considered as a household symptom and were ordinarily managed with over-the-counter drugs which delayed presentation of Septal hematoma/abscess to the specialist.

In this study, the most common clinical feature of nasal septal hematoma/abscess was nasal obstruction found in all the patients. This is the resultant effect of the combination of nasal septal inflammation, edema, and accumulation of blood or pus which compromise the nasal airflow. Research work from other studies reported similar findings [21,22,23]. Subsequently, this will

lead to mouth breathing with occasional snoring. On clinical examination, a bulbous bluish or reddish hue over the nasal septal mucosa is a pointer to nasal septal hematoma/abscess. Complete intranasal examination with anterior rhinoscopy in all cases of nasal septal hematoma/abscess is essential for further findings such as the extent of the abscess, intranasal laceration, dislocation, and fractures. Needle aspiration was conducted on the nasal septum for all the participants and the nature of the aspirate will confirm the diagnosis (pus or blood), relieve pressure, and provide a specimen for microscopy culture and sensitivity.

Majority of the nasal septal aspirate yields growth of respiratory tract microorganism. This proofs that nasal septal abscess in this study was due mainly to sinonasal infections. Majority of isolated microorganisms were *Staphylococcus aureus*, *Streptococcus* and *Haemophilus influenzae*. This contradicts other studies which emphasis that nasal septal hematoma/abscess are secondary to nasal and facial trauma [24,25,22].

For patients with nasal septal hematoma/abscess, Computerized Tomography (CT) scanning is required. CT scan is necessary to rule out complications such as intracranial extension. CT Scan is indicated with the following findings: Extensive facial cellulitis, periorbital cellulitis, meningitis, loss of consciousness and localizing neurological signs and treatment failure.

Complications recorded in this work includes recurrent cases, facial cellulitis, and nasal septal edema.

While some earlier studies showed some complicated cases with their record, this study also showed similar complications [26,27]. Nasal skeletal (cartilage and bone) with soft tissue damage were minimal in our findings and did not result into septal deviation, nasal obstruction, and deformed nasal external pyramid at the end of the 6 weeks clinical follow-up. This may be explained by the type and stages of reported cases in the study. A further reason may be virulence of the offending organism, stage of presentation and management techniques.

5. CONCLUSION

Nasal septal hematoma/abscess is not a commonly encountered sinonasal condition with

a high index of suspicion in patients with a long-standing nasal obstruction. Infection and trauma are the most frequent etiology and early presentation of nasal septal hematoma/abscess with prompt diagnosis, and treatment provides a good prognosis. Treatment by incision and drainage, intranasal packing, with the insertion of drain and antibiotics coverage is an effective treatment modality which preserves the functional and aesthetic of the nose.

CONSENT

As per international standard or university standard, patient's written consent has been collected and preserved by the authors.

ETHICAL APPROVAL

As per international standard or university standard, written approval of Ethics committee has been collected and preserved by the authors.

COMPETING INTERESTS

Authors have declared that no competing interests exist.

REFERENCES

1. Menger DJ, Tabink I, Nolst TG. Treatment of septal hematomas and abscesses in children. *Facial Plast Surg.* 2007;23(4): 239-43.
2. Matthew DJ. Functional Rhinoplasty. Management of pediatric nasal surgery (Rhinoplasty). *Facial Plastic Surgery Clinics of North America.* 2017;25(2):211–21.
3. Afolabi OA, Salisu A, Adeyemo AA, Ijaluola GT. Nasal septal abscess in Ibadan Nigeria. *Tropical Journal of Health Sciences.* 2009;16(2):25-7.
4. Schwartz JM. Nasal septal abscess. *Consultant.* 2007;5:47.
5. Verwoerd CD, Verwoerd-Verhoef HL. Rhinosurgery in children: Developmental and surgical aspects. *Laryngorhinotologie.* 2010;89(1):S46-71.
6. Salam B, Camilleri A. Non-traumatic nasal septal abscess in an immunocompetent patient. *Rhinology.* 2009;47:476–7.
7. Sandel VH, Davison SP. Three spontaneous occurrences of nasal septal abscess in patients with chronic asymptomatic HIV – the need for early intervention and reconstruction. *Ear Nose Throat J.* 2009;88:1058–66.
8. Walker R, Gardner L, Sindwani R. Fungal nasal septal abscess in the immunocompromised patient. *Otolaryngol Head Neck Surg.* 2007;136:506–7.
9. Adobamen PR. Management of nasal septal abscess in Nigeria. *Niger J General Pract.* 2011;9(2):28–30.
10. Menachem, Gross Ron, Eliashar. Nasal septal hematoma with abscess: An unusual complication of nasal injury. 2004; 35(1):1–2.
11. Toback S. Nasal septal hematoma in an 11-month – old infant: A case report and review of literature. *Pediatr Emerg Care.* 2003;19:265–7.
12. Alshaikh N, Lo S. Nasal septal abscess in children: From diagnosis to management and prevention. *Int J Pediatr Otorhinolaryngol.* 2011;75(6):737-44.
13. Dirk JM, Ivar CT, Gilbert JN. Nasal septal abscess in children: Reconstruction with autologous cartilage grafts on polydioxanone plate. *Arch Otolaryngol Head Neck Surg.* 2008;134(8):842-7.
14. Huang PH, Chiang YC, Yang TH, Chao PZ, Lee FP. Nasal septal abscess. *Otolaryngol Head Neck Surg.* 2006; 135(2):335-6.
15. Savage RR, Valvich C. Hematoma of the nasal septum. *Pediatr Rev.* 2006;27(12): 478-9.
16. Sanyaolu LN, Farmer SE, Cuddihy PJ. Nasal septal hematoma. *BMJ.* 2014;349.
17. Sayin I, Yazici ZM, Bozkurt E, Kayhan FT. Nasal septal hematoma and abscess in children. *J Craniofac Surg.* 2011;22(6): e17–e19.
18. Linl IH, Huang S. Nasal septal abscess complicated with acute sinusitis and facial cellulitis in a child. *Auris Nasus Larynx.* 2007;34(2):241–3.
19. Tien DA, Krakovitz P, Anne S. Nasal septal abscess in association with pediatric acute rhinosinusitis. *International Journal of Pediatric Otorhinolaryngology.* 2016;91: 27–9.
20. Hassani R, Aderdour L, Maliki O, Boured A, Elfakiri MM, Bouchoua F, Raji A. Nasal septal abscess complicating acute sinusitis in a child. *Archives de Pédiatrie.* 2011; 18(1):15–7.
21. Cheng LH, Kang BH. Nasal septal abscess and facial cellulitis caused by

- community-acquired methicillin-resistant *Staphylococcus aureus*. J Laryngol Otol. 2010;124(9):1014-6.
22. Khedim A, Ben Slimene S, Faidi A, Mansour S, Bel Hadj Yahia S, Chtioui I. A case of nasal septum abscess. Médecine et Maladies Infectieuses. 2007;37:S260–S263.
 23. Yi C, Anjali S, Joseph HJR. Clinical Communications. Pediatric spontaneous nasal septal abscess presenting as a soft tissue mass in a child. The Journal of Emergency Medicine. 2017;52(4):e129–e132.
 24. George A, Smith WK, Kumar S, Pfliegerer AG. Posterior nasal septal abscess in a healthy adult patient. The Journal of Laryngology & Otology. 2008;122(12): 1386-8.
 25. Huang WH, Hung PK. Methicillin-resistant *Staphylococcus aureus* infections in acute rhinosinusitis. Laryngoscope. 2006;116: 288–91.
 26. Pei-Hsuan H, Yuh-Chyun C, Fei-Peng L. Nasal septal abscess. Otolaryngology-Head and Neck Surgery. 2006;135(2): 335–6.
 27. Tan NW, Turvey SE, Byrne AT, Ludemann JP, Kollmann TR. *Staphylococcus aureus* nasal septal abscess complicated by extradural abscess in an infant. J Otolaryngol Head Neck Surg. 2012;41(1): E7-12.

© 2018 Adegbi et al.; This is an Open Access article distributed under the terms of the Creative Commons Attribution License (<http://creativecommons.org/licenses/by/4.0>), which permits unrestricted use, distribution, and reproduction in any medium, provided the original work is properly cited.

Peer-review history:

The peer review history for this paper can be accessed here:
<http://www.sciencedomain.org/review-history/26248>