



# Evaluation of the Effectiveness of Titanium-prepared Platelet rich Fibrin (T-PRF) and Demineralized Freeze-dried Bone Allograft (DFDBA) in Socket Preservation Followed by Implant Placement Using Two Stage Approach

Ranu Oza <sup>a\*</sup> and Prasad V. Dhadse <sup>a°</sup>

<sup>a</sup> Department of Periodontics and Implantology, Sharad Pawar Dental College and Hospital, Datta Meghe Institute of Medical Sciences (DU), Sawangi (Meghe), Wardha (Maharashtra), India.

## Authors' contributions

This work was carried out in collaboration between both authors. Both authors read and approved the final manuscript.

## Article Information

DOI: 10.9734/JPRI/2021/v33i60B35074

## Open Peer Review History:

This journal follows the Advanced Open Peer Review policy. Identity of the Reviewers, Editor(s) and additional Reviewers, peer review comments, different versions of the manuscript, comments of the editors, etc are available here: <https://www.sdiarticle5.com/review-history/80083>

Study Protocol

Received 20 October 2021  
Accepted 26 December 2021  
Published 28 December 2021

## ABSTRACT

**Background:** The focus of the implant therapy is now shifting to a stable restoration rather than mere osseointegration. Placement of dental implants has become an indispensable part of mainstream dentistry, offering an improved quality of life to patients. One of the physiological changes that occurs after tooth extraction is alveolar ridge resorption. A variety of bone graft materials and platelet concentrates which are abundant in growth factors have been incorporated that provides the added effect of combination for early and better healing.

**Objectives:** Evaluation of effectiveness of Titanium Prepared Platelet Rich Fibrin (T-PRF) and Demineralized Freeze-Dried Bone Graft (DFDBA) in socket preservation and simultaneous evaluation of implant stability three months after implant placement using two stage protocol.

**Methodology:** Present study will be performed over one year period. Twelve patients, each having one tooth indicated for extraction in either of the arches will be selected. Atraumatic extraction will

<sup>≡</sup> Dr., Postgraduate Student;

<sup>°</sup> Dr., Professor and Head;

\*Corresponding author: E-mail: ranuoza@gmail.com;

be done followed by socket preservation using combination of T-PRF and DFDBA to promote early healing followed by placement of implant.

**Expected Results:** We expect early and better results of bone formation in healing sockets after preservation using T-PRF and DFDBA, which will be advantageous for implant placement. Better results in terms of bone volume, bone height, bone density and histomorphometry are expected.

**Conclusion:** Combined effect of DFDBA and T-PRF is expected to improve the periodontal parameters including both soft tissue and hard tissue outcomes.

*Keywords: T-PRF; socket preservation; dental implant; DFDBA.*

## 1. INTRODUCTION

The most popular and predictable treatment strategy practiced for rehabilitation of complete or partially edentulous arches of patients are dental implants. The focus of implant therapy is now moving from osseointegration to a safe reconstruction, and the timing of implant placement after extraction is one of the key factors in this. The primary indicator for the repair or preservation of osseous structures following disease or trauma is the rehabilitation of edentulous ridges to allow the installation of endosseous implants. One of the physiological changes that occurs after tooth extraction is alveolar ridge resorption [1]. Socket grafting, which also requires the use of grafting materials with or without barrier membranes, is said to minimise dimensional shrinkage in the alveolar ridge after tooth extraction [2].

Fresh-frozen, freeze-dried, or demineralized freeze-dried allograft have been shown to have less immunogenicity and sufficient bioavailability [3]. The most commonly clinically accepted or adapted bone allograft material for periodontal repair is Demineralized freeze-dried bone allograft (DFDBA) [4]. as it is known for its property of Osseo induction due to presence of BMPs. It is mainly used for reconstruction of osseous defects [5].

Use of plasma fractions having increased concentration of platelets like Platelet-rich plasma (PRP) offers numerous advantages. They play important role in regeneration. Their use is successfully associated with healing of connective tissue and bone. PRP shows non stimulative property and supports bioactivity. It also has variation patterns of methods showing technique sensitivity. On the other side PRP preparation requires time. Hence attempts have been made to improve the quality and improve the PRP properties. One of them is Titanium Platelet Rich Fibrin(T-PRF) [6]. It is third generation platelet concentrate, and is known to

eliminate the hazardous effect seen with silica, present in the glass vacuum containers used for the preparation of Platelet Rich Fibrin (PRF).

In the study by Olgun et al in the year 2018, use of titanium-prepared platelet rich fibrin (T-PRF) and allograft was compared and evaluated when used in sinus lifting technique wherein no systemic and local complications were recorded. Clinical, radiographic, and histological results, studies have shown that bone formation is accelerated to 4 months compared to 6 months for allografts [7]. In this current study we will be evaluating the combined effect of the use of T-PRF and DFDBA for socket preservation after that, a dental implant is placed using two stage protocol. Our study plan will serve many advantages including reduced time and improved healing outcome, with simultaneous preservation of adequate bone height.

The aim of this study is to assess the combined effect of Titanium Platelet Rich Fibrin (T-PRF) and Demineralized Freeze-Dried Bone Graft (DFDBA) in socket preservation, as well as implant stability, three months after implant placement, using a two-stage protocol.

## 2. METHODS AND MATERIALS

### 2.1 Study Population

In this study, around twelve healthy patients with no history of any systemic disease aged between 20 to 55 years will be recruited based on the need for single tooth replacement through implant fixture, from Department of Periodontics, Sharad Pawar Dental College, Sawangi (Meghe), Wardha.. Before initiating this study, the subjects will be acquainted with the purpose, method and design of the study. Informed consent will be obtained in written. Patients should fulfill the following criteria for involvement in study.

## 2.2 Inclusion Criteria

1. Tooth indicated for extraction. Reasons might be any one like, fracture of root, failure of endodontic treatment, resorption (internal and external), over-retained primary teeth, non-restorable carious lesions, residual roots.
2. Oral hygiene indicated with plaque score  $\leq$  25%.
3. Presence of opposing natural tooth.
4. Presence of adjacent teeth.
5. Thick gingival biotype.
6. Radiographic and clinical appearance of intact alveolar bony walls.
7. 4 mm of bone radiographically at root apex
8. D-1, D-2 or D-3 bone quality.

## 2.3 Exclusion Criteria

1. Patients with impaired systemic health that would interfere with the process involved with repair and healing of bones e.g. (Diabetes mellitus, Osteoporosis, Blood disorders, and Titanium allergy).
2. Significant differences in maxilla-mandibular space.
3. Presence of para functional habits such as bruxism or clenching.
4. Presence of proclined teeth, teeth with interdental spacing, rotated or mal-aligned anterior teeth.
5. History of alcoholism, excessive smoking or drug abuse.
6. D-4 bone quality.
7. Width of keratinized gingiva less than 2mm at implant site.
8. Debilitating temporo-mandibular joint pathosis.
9. Untreated dental diseases.
10. Pregnant and lactating mothers.

## 2.4 Study Plan

Present study will be performed over one year period. Twelve patients, each having one tooth indicated for extraction in either or both the arches will be selected. Baseline parameters will be recorded both clinically using UNC-15 probe and radiographically using CBCT. Extraction will be done atraumatically with minimal flap reflection using periostomes. Post-extraction sockets will be augmented using a combination of T-PRF and DFDBA. At three months, a clinical and radiographic examination will be performed,

and implants will be implanted using a two-stage procedure. Three months after implant placement, the second stage surgery will be done. Both patients will have their Modified Plaque Index and Gingival Index registered. Probing depth at four sites around implants (mesial, buccal, distal and lingual/palatal) will be measured using UNC 15 probe and mobility of implants according to clinical implant mobility scale will be assessed at baseline and 3 months after permanent restoration. CBCT (Cone Beam Computed Tomography) will be done at baseline and 3 months after implant placement. Histomorphometric analysis will be done after receiving bone samples during implant placement.

## 2.5 Initial Therapy

After a thorough evaluation and diagnosis, full mouth ultrasonic scaling will be administered, followed by initial therapy consisting of oral hygiene instructions. Plaque control instructions will be provided to the patients until they have a plaque score of less than 25%. A diagnostic cast of each patient will be prepared prior to surgery to determine the maxilla-mandibular relationship. To ensure proper implant placement, a diagnostic wax up of the teeth to be replaced will be prepared. Throughout the process, clinical images will be taken of all patients.

## 2.6 Surgical Procedure


1 hour prior to surgery, all patients will be given a prophylactic antibiotic, which will contain Cap Amoxicillin 500g. Depending on the surgical site, the area to be operated on may be anaesthetized with a nerve block and/or infiltration anaesthesia using a local anaesthetic solution. Lignocaine solution containing 1:100,000 Adrenaline at a concentration of 2%

## 2.7 Extraction of Tooth

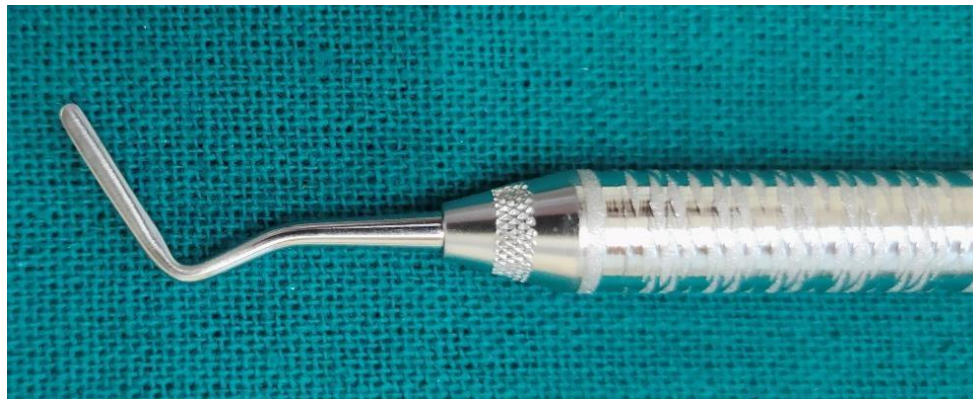Traditional extraction procedures include severing the periodontal connection, luxation with an elevator, and removal with forceps, which often result in tooth fracture, surrounding bone fracture, or both, as well as major ridge deformities after healing [8]. Such deformities can prevent dental implant placement or result in sub-pontic food traps beneath typical fixed partial dentures, in addition to compromising aesthetics. To prevent these problems, "atraumatic" dental extraction procedures have gained popularity,

and they could eventually become the standard of care for tooth extraction. Atraumatic tooth extraction is a technique used to carefully remove a tooth in such way that it reduces or eliminates the trauma to the tissues preserving the remaining bone around the teeth [9]. The surgical protocol will be followed with complete asepsis and infection control. Atraumatic extraction will be done using periotomes. Every

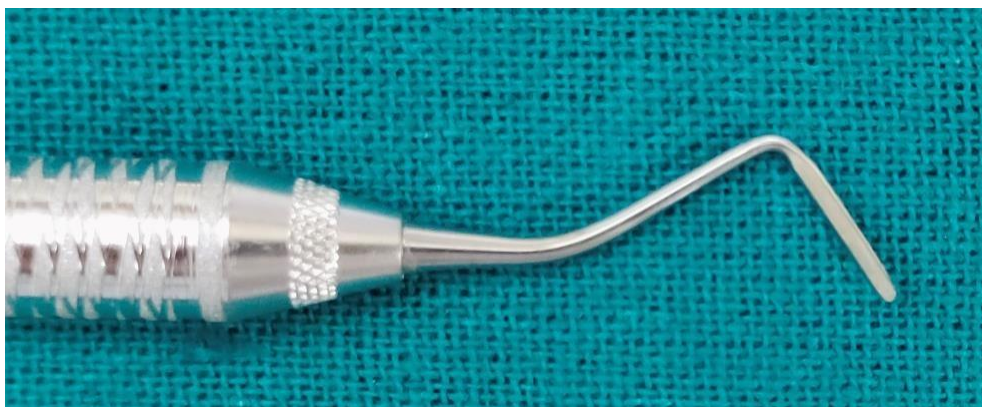attempt will be made to minimize trauma to the alveolus during extraction with minimum socket expansion. Following the induction of local anaesthesia, the number 15 surgical blade would be inserted interproximally, that is, mesially and distally, in order to luxate the tooth inside the socket without breaking the cortical plates and to extreme the periodontal ligament fibres.



**Fig. 1. (Anterior and posterior Periotomes)**



**Fig. 2. (Anterior Periotome)**



**Fig. 3. (Posterior Periotome)**



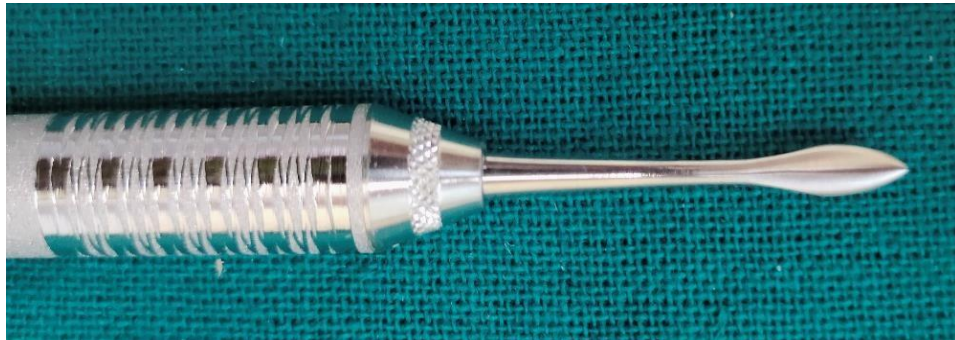

Fig. 4. (Anterior Periotome)

## 2.8 Alveolar Ridge Preservation Procedure

After the tooth extraction, sockets will be examined for integrity of socket walls and debridement will be carried out. It will be followed by bone grafting using combination of T- PRF and DFDBA. 3 months after socket preservation implant placement will be done. Metal- ceramic crowns will be fabricated in the laboratory.

Titanium PRF test tubes are procured from Çanakkale Onsekiz Mart University, Faculty of Dentistry, Department of Periodontology, 17100 Çanakkale, TURKEY as shown in following Figs. 5-8.

## 2.9 Re – Evaluation

A complete re-evaluation will be performed at 3 months after placement of definitive metal – ceramic restoration. All clinical parameters, such as “full mouth plaque index (MPI)”, “full mouth papillary bleeding index (MBI)”, and probing measurements around implants as well as

clinical implant mobility scale [10] (CIMS) will be assessed.

## 2.10 Statistical Analysis

The Mean  $\pm$  SD (mean and standard deviations) values will be determined for each clinical periodontal parameter including “PI, PBI, PPD, WKG, CAL, PH, PIS and marginal bone level”. The mean data will then be subjected for statistical analysis from baseline to 2 months. For all of the patients, the Student's paired test will be used to equate baseline to 2 month results. The difference observed will be considered non-significant if the probability value (p) is greater than 0.05, and significant if the value is less than 0.05.

**Expected Outcomes:** We expect early and better results in healing after socket preservation using T-PRF and DFDBA, which will be advantageous for implant placement. Better results in terms of bone volume, bone height, bone density and histomorphometric results.



Fig. 5. (Titanium test tubes)



Fig. 6. (Length: 12.5 cm)




Fig. 7. (Diameter 10mm/1cm)

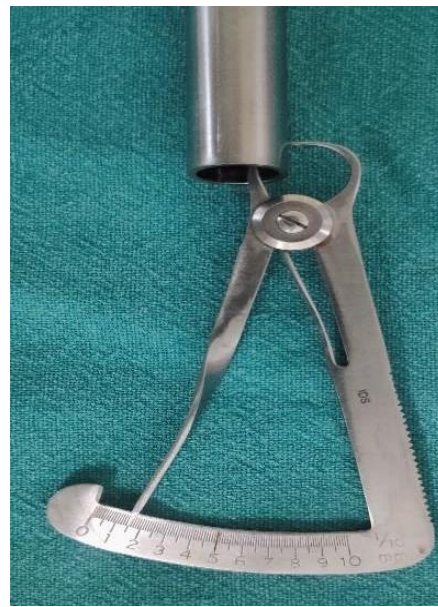

Fig. 8. (Thickness 1.5mm)

### 3. DISCUSSION

Titanium is one of the metals with the highest strength-to-weight ratios and corrosion resistance [11]. Titanium has good biocompatibility due to its noncorrosive characteristics. In vivo, the material forms an adhesive oxide layer to passivate itself. Titanium also has a unique osseointegration feature that allows it to integrate structurally and functionally with the underlying bone, making it a popular material for total joint replacements [12], dental implants, internal and external fixators, artificial heart valves, spinal fusion, and medical devices [13]. Biomaterials that come into touch with blood must have a high level of hemocompatibility. As a result, titanium is a promising biocompatible material for biomedical devices, whether in orthopaedics or cardiology.

In the study by Olgun et al in the year 2018, use of "titanium-prepared platelet rich fibrin (T-PRF)" and "allograft" was compared and evaluated when used in sinus lifting technique. Comparisons were based on histologic, radiographic basis after evaluating clinically. Sinus-lifting procedures were done on 18 posterior maxilla. Balloon-lifting technique was selected and implants were placed. Randomization was done and around 10 sinuses were allotted to "T-PRF" (test group) and to allograft eight were assigned (control group). Computed tomography was done at 4 and 6 months in both the groups respectively. Bone

samples were received during implant surgery. Implant stability was measured after three months of the second surgery. Results of the study stated that the control group had improved findings. (69% height, 53% density, and 62% volume) than "T-PRF" group. Newly-formed bone ratios were evaluated histomorphometrically. In the control and test groups, they were about 17.28 2.53 and 16.58 1.05, respectively. There was no discernible difference between the two classes. Implant stability values were found to be statistically significant ( $P = .611$ ). Finally, the authors concluded that T-PRF treatment results in better clinical outcomes and histomorphometric results, as well as faster bone development.

A case report by Shantipriya Reddy et al, 2018 two intrabony defects treated with T-PRF were reported. Clinical evaluation was then followed by radiographic evaluation and outcomes were assessed. Surgical treatment with placement of autologous T-PRF was followed for a period of six months. After six months it showed a significant decrease in the values of "Probing Depth" (PD) and gain in the values of "Relative Attachment Level" (RAL). Radiographic observations showed defect depth reduction and increase in bone density. It demonstrated, the presence of growth factors in "T-PRF" have an improving effect on healing of various hard and soft tissues. Finally, the authors came to the conclusion that "T-PRF" is effective at enhancing clinical and radiographic parameters. It implies

that "T-PRF" has a significant role to play as a key regenerative material in the treatment of intrabony osseous defects. Few other related studies on intraoral implants were reported [11-14].

Therefore, in this study we plan to associate the effectiveness of implants incorporated in fresh extraction socket with simultaneous placement of titanium platelet rich fibrin and demineralized freeze-dried bone graft using a two-stage protocol. Our study plan will serve many advantages including reduced number of surgical interventions, preservation of adequate bone height and esthetic outcomes.

#### 4. CONCLUSION

Combination of T-PRF and DFDBA will expect novel outcomes with reduced time for healing. This study plan will serve many advantages including reduced time for healing, improved healing and preservation of adequate bone height.

#### CONSENT

As per international standard or university standard, patients' consent will be written.

#### ETHICAL APPROVAL

Study protocol is approved by the Institutional Ethics Committee of Datta Meghe Institute of Medical Sciences, Sawangi (Meghe), Wardha.

#### COMPETING INTERESTS

Authors have declared that no competing interests exist.

#### REFERENCES

- Schropp L, Wenzel A, Kostopoulos L, Karring T. Bone healing and soft tissue contour changes following single-tooth extraction: a clinical and radiographic 12-month prospective study. *Int J Periodontics Restorative Dent.* 2003;23(4):313–23.
- Fiorellini JP, Howell TH, Cochran D, Malmquist J, Lilly LC, Spagnoli D, et al. Randomized Study Evaluating Recombinant Human Bone Morphogenetic Protein-2 for Extraction Socket Augmentation. *J Periodontol.* 2005;76(4): 605–13.
- Jamjoom A, Cohen R. Grafts for Ridge Preservation. *J Funct Biomater.* 2015; 6(3):833–48.
- Libin BM, Ward HL, Fishman L. Decalcified, Lyophilized Bone Allografts for Use in Human Periodontal Defects. *J Periodontol.* 1975;46(1):51–6.
- Srivastava R, Verma P, Tripathi V, Tripathi P. Demineralized freeze-dried bone allograft in treatment of interproximal vertical defect - a clinical report. *Tanta Dent J.* 2016;13(4):213.
- Tunalı M, Özdemir H, Küçükodacı Z, Akman S, Yaprak E, Toker H, et al. A Novel Platelet Concentrate: Titanium-Prepared Platelet-Rich Fibrin. *BioMed Res Int.* 2014;2014:1–7.
- Olgun E, Ozkan SY, Atmaca HT, Yalim M, Hendek MK. Comparison of the clinical, radiographic, and histological effects of titanium-prepared platelet rich fibrin to allograft materials in sinus-lifting procedures. *J Investig Clin Dent.* 2018;9(4):e12347.
- Araujo MG, Lindhe J. Dimensional ridge alterations following tooth extraction. An experimental study in the dog. *J Clin Periodontol.* 2005;32(2):212–8.
- Jain A, Sridevi U. An innovative approach for atraumatic tooth extraction for immediate implant placement by using Sopian extraction kit: A case report. *Dent Oral Craniofacial Res [Internet].* 2016 [cited 2021 May 21];2(2). Available:<http://oatext.com/An-innovative-approach-for-atraumatic-tooth-extraction-for-immediate-implant-placement-by-using-Sopian-extraction-kit-A-case-report.php>
- Misch CE. The implant quality scale: a clinical assessment of the health--disease continuum. *Oral Health.* 1998;88(7):15–20, 23–5; quiz 25–6.
- Learning From Nature How To Design New Implantable Materials [PDF] [6h3m4acn83r0] [Internet]. [Cited 2022 Jan 20]. Available:<https://vdoc.pub/documents/learning-from-nature-how-to-design-new-implantable-materials-6h3m4acn83r0>
- Sanz M, Dahlin C, Apatzidou D, Artzi Z, Bozic D, Calciolari E, et al. Biomaterials and regenerative technologies used in bone regeneration in the craniomaxillofacial region: Consensus report of group 2 of the 15th European Workshop on Periodontology on Bone Regeneration. *J Clin Periodontol.* 2019;46:82–91.

13. Yumpu.com. Introduction to Materials - biomaterials [Internet]. yumpu.com. [Cited 2022 Jan 20]. Available:<https://www.yumpu.com/en/document/view/63056668/introduction-to-materials-biomaterials>

---

© 2021 Oza and Dhadse; This is an Open Access article distributed under the terms of the Creative Commons Attribution License (<http://creativecommons.org/licenses/by/4.0>), which permits unrestricted use, distribution, and reproduction in any medium, provided the original work is properly cited.

*Peer-review history:*  
*The peer review history for this paper can be accessed here:*  
<https://www.sdiarticle5.com/review-history/80083>