

Co-existing acute appendicitis and segmental infarction: Report of a case and review of the literature

Chin-Ta Lin¹, Chieh-Wen Lin², Shih-Ming Kuo³,
Guan-Yeu Diau⁴, Ke-Chi Chen⁵

ABSTRACT

Omental infarction is a rare entity in children, especially coexisting with acute appendicitis. We present a case of a 6-year old child presenting with abdominal pain with fever, anorexia, and leukocytosis. The child underwent surgery with preoperative diagnosis of acute appendicitis according to the findings of sonography. The definitive diagnosis of an infarcted segment of right side of the greater omentum and acute appendicitis was made intraoperatively and confirmed pathologically. As the etiology is unknown, we surgeons should be aware of the coincident intraperitoneal pathological condition of acute appendicitis and segmental infarction to avoid further complications.

KEY WORDS: Acute abdomen, Segmental infarction, Appendicitis, Sonography, Child.

Pak J Med Sci April - June 2011 Vol. 27 No. 2 441-443

How to cite this article:

Lin CT, Lin CW, Kuo SM, Diau GY, Chen KC. Co-existing acute appendicitis and segmental infarction: Report of a case and review of the literature. Pak J Med Sci 2011;27(2):441-443

INTRODUCTION

Idiopathic segmental infarction of the greater omentum is an uncommon cause of acute abdomen occurring in approximately 0.1% of children that undergo laparotomy for suspected appendicitis.¹ The etiology is still unclear and the clinical diagnosis usually is not confirmed until laparotomy.² Segmental infarction presenting with acute appendicitis is more infre-

quent. Here, we report a case of coexisting with segmental infarction and acute appendicitis successfully managed with laparoscopic surgery.

CASE REPORT

A 6-year-old child presented to the emergency department with a one-day history of abdominal pain with nausea. There were no changes in bowel habit and body weight. In her medical history, there was no growth problem or previous operation. Her vital signs revealed temperature of 38.3 °C, pulse of 104 /min and blood pressure of 117/76 mmHg. Physical examination revealed no palpable mass but tenderness in the right lower quadrant (RLQ) with muscle guarding. There is no remarkable finding on digital examination.

The blood tests showed white blood count of 13500/ mm³ with 90% segmented neutrophils. Plain film of the abdomen revealed increased bowel gas pattern in the central abdomen. Abdominal sonography showed a non-compressible, dilated blind-end tubular structure about 0.5 cm in diameter over RLQ of the abdomen (Fig-1). Therefore, the patient underwent laparoscopic appendectomy with the diagnosis of acute appendicitis.

1. Chin-Ta Lin,
 2. Chieh-Wen Lin,
 3. Shih-Ming Kuo,
 4. Guan-Yeu Diau,
 5. Ke-Chi Chen,
- 1-5: Division of Pediatric Surgery, Dept. of Surgery, Tri-Service General Hospital, National Defense Medical Center, Taipei, Taiwan.

Correspondence:

Ke-Chi Chen, MD,
Division of Pediatric Surgery, Department of Surgery,
Tri-Service General Hospital,
No. 325, Sec. 2,
Cheng-Gung Road, Neihu 114,
Taipei, Taiwan.
E-mail: aarondakimo@yahoo.com.tw

- * Received For Publication: December 15, 2010
- * Revision Received: February 10, 2011
- * Revision Accepted: February 11, 2011

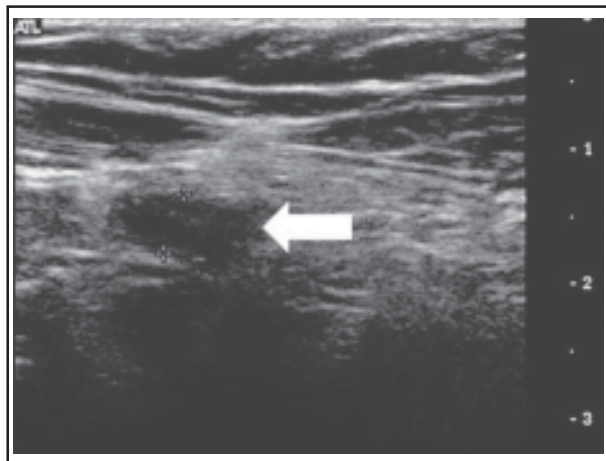


Fig-1: Ultrasound of abdomen demonstrated a non-compressible, dilated blind-end tubular structure, about 0.5 cm in diameter (white arrow), over right lower quadrant (RLQ) of the abdomen.

At operation, the right segment of greater omentum localized at the inferior right quadrant region was found to be congestive and cyanotic (Fig-2A). Adhesions between the greater omentum and the right abdominal wall were seen. The appendix was grossly edematous and erythematous (Fig-2B). Pathology reports are compatible with acute appendicitis with segmental infarction. The postoperative course was uneventful and the patient was discharged on the 3rd postoperative day.

DISCUSSION

Acute appendicitis is frequently encountered in clinical practice because it is the most common cause of pediatric abdominal emergency.³ In contrast, segmental infarction is rarely considered as part of the

differential diagnosis for acute abdominal pain due to its rare occurrence.⁴ It is estimated that segmental infarction is found in about 0.1% to 0.5% of children undergoing operations for acute appendicitis.¹ Although segmental infarction was first described by Bush early in 1896,⁵ the exact etiology and pathogenesis of this condition is still unknown.

Clinically, 90% of segmental infarctions are known involving right epiploic vessels and usually causing right lower quadrant of abdominal pain,^{6,7} which is difficult to be distinguished from acute appendicitis. Thus, ultrasound (US) of abdomen might be helpful in not only establishing the preoperative diagnosis, but also excluding other possible diseases. Rimon et al. even showed that early identification of segmental infarction by abdominal US appears to prevent unjustified surgical procedures and reduce the length of hospital stay.⁸

However, segmental infarction is a self-limiting disease known to resolve spontaneously in children.⁹ Complete resolution of symptoms usually occurred within two weeks. Nevertheless, some studies still suggest operation to avoid the complications of adhesions forming with the segmental infarction, causing obstruction of nearby bowel loops.¹⁰ Furthermore, if the segmental infarction were involved with acute appendicitis, as in our case, surgical management should be indicated.

In conclusion, we report this rare case to show that acute appendicitis could occur along with segmental infarction. Although rare, segmental infarction should be considered when evaluating possible causes of abdominal pain. The diagnostic modality by using abdominal ultrasound may improve diagnostic accuracy with appropriate delineation of the relevant

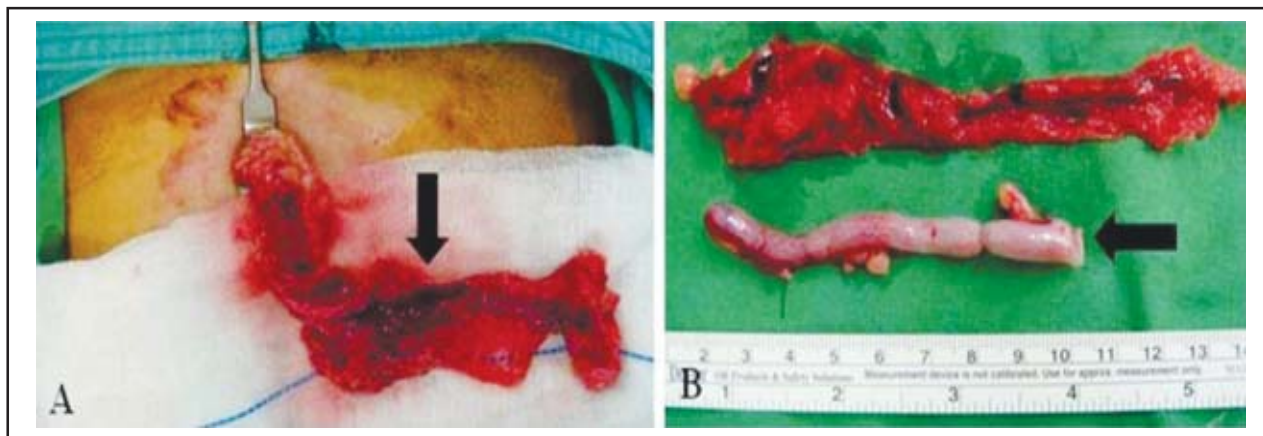


Fig-2: At operation, the right segment of greater omentum localized at the inferior right quadrant region (black arrow) was found to be congestive and cyanotic (Fig-2A). The appendix (black arrow) was edematous and erythematous (Fig-2B).

anatomy of the underlying lesions. Furthermore, no matter what the visceral organs are found to be normal or not at exploration, the omentum should be inspected for infarction.

REFERENCES

1. Sweeney MJ, Blestel GA, Ancalmo N. Primary torsion of the greater omentum. A rare cause of abdominal pain in children. *JAMA*. 1983;249:3073.
2. Goti F, Hollmann R, Stieger R. Idiopathic segmental infarction of the greater omentum successfully treated by laparoscopy: Report of case. *Surg Today*. 2000;30:451-453.
3. Tseng YC, Lee MS, Chang YJ, Wu HP. Acute abdomen in pediatric patients admitted to the pediatric emergency department. *Pediatr Neonatol*. 2008;49(4):126-134.
4. Helmraath MA, Dorfman SR, Minifee PK, Bloss RS, Brandt ML, DeBakey ME. Right lower quadrant pain in children caused by omental infarction. *Am J Surg* 2001;182:729-732.
5. Bush P. A case of haemorrhage into the greater omentum. *The Lancet*. 1896;147:286.
6. Puylaert JBCM. Right-sided segmental infarction of the omentum: Clinical, US, and CT findings. *Radiology*. 1992;185:169-172.
7. Sanchez J, Rosado R, Ramirez D, Medina P, Mezquita S, Gallardo A. Torsion of the greater omentum: Treatment by laparoscopy. *Surg Laparosc Endosc Percutan Tech*. 2002;12:443-445.
8. Rimon A, Daneman A, Gerstle JT, Ratnapalan S. Omental infarction in children. *J Pediatr*. 2009;155(3):427-431.
9. Nagar H, Kessler A, Ben-Sira L, Klepikov I, Wiess J, Graif M. Omental infarction: an unusual cause of acute abdomen in children. *Pediatr Surg Int*. 2003;19:677-679.
10. Loh MH, Chui HC, Yap TL, Sundfor A, Tan CE. Omental infarction: A mimicker of acute appendicitis in children. *J Pediatr Surg*. 2005;40:1224-1226.