



## Versatility of the ventral approach in bulbar urethroplasty using dorsal, ventral or dorsal plus ventral oral grafts

Enzo Palminteri, Elisa Berdondini, Ferdinando Fusco, Cosimo De Nunzio, Kostas Giannitsas & Ahmed A. Shokeir

To cite this article: Enzo Palminteri, Elisa Berdondini, Ferdinando Fusco, Cosimo De Nunzio, Kostas Giannitsas & Ahmed A. Shokeir (2012) Versatility of the ventral approach in bulbar urethroplasty using dorsal, ventral or dorsal plus ventral oral grafts, Arab Journal of Urology, 10:2, 118-124, DOI: [10.1016/j.aju.2012.02.009](https://doi.org/10.1016/j.aju.2012.02.009)

To link to this article: <https://doi.org/10.1016/j.aju.2012.02.009>



© 2012 Arab Association of Urology



Published online: 05 Apr 2019.




Submit your article to this journal [↗](#)



Article views: 212



View related articles [↗](#)



## ONCOLOGY/RECONSTRUCTION

### ORIGINAL ARTICLE

# Versatility of the ventral approach in bulbar urethroplasty using dorsal, ventral or dorsal plus ventral oral grafts

Enzo Palminteri <sup>a,\*</sup>, Elisa Berdondini <sup>a</sup>, Ferdinando Fusco <sup>b</sup>, Cosimo De Nunzio <sup>c</sup>,  
Kostas Giannitsas <sup>d</sup>, Ahmed A. Shokeir <sup>e</sup>

<sup>a</sup> Center for Urethral and Genitalia Reconstructive Surgery, Arezzo, Italy

<sup>b</sup> Department of Urology, University Federico II, Naples, Italy

<sup>c</sup> Department of Urology, Sant'Andrea Hospital, 'La Sapienza' University, Rome, Italy

<sup>d</sup> Urology Department, Patras University Hospital, Patras, Greece

<sup>e</sup> Urology & Nephrology Center, Mansoura, Egypt

Received 12 January 2012, Received in revised form 24 February 2012, Accepted 25 February 2012

Available online 20 April 2012

#### KEYWORDS

Urethra;  
Stricture;  
Urethroplasty;  
Buccal mucosa;  
Graft

#### ABBREVIATIONS

AU, anastomotic urethroplasty; BM, buccal mucosa;  
(D)(V)(DV)GU, (dorsal) (ventral) (dorsal

**Abstract Objectives:** To investigate the versatility of the ventral urethrotomy approach in bulbar reconstruction with buccal mucosa (BM) grafts placed on the dorsal, ventral or dorsal plus ventral urethral surface.

**Patients and methods:** Between 1999 and 2008, 216 patients with bulbar strictures underwent BM graft urethroplasty using the ventral-sagittal urethrotomy approach. Of these patients, 32 (14.8%; mean stricture 3.2 cm, range 1.5–5) had a dorsal graft urethroplasty (DGU), 121 (56%; mean stricture 3.7, range 1.5–8) a ventral graft urethroplasty (VGU), and 63 (29.2%; mean stricture 3.4, range 1.5–10) a dorsal plus ventral graft urethroplasty (DVGU). The strictured urethra was opened by a ventral-sagittal urethrotomy and BM graft was inserted dorsally or ventrally or dorsal plus ventral to augment the urethral plate.

**Results:** The median follow-up was 37 months. The overall 5-year actuarial success rate was 91.4%. The 5-year actuarial success rates were 87.8%, 95.5% and

\* Corresponding author. Address: Centre for Urethral and Genitalia Reconstructive Surgery, Via Fra' Guittone 2, 52100 Arezzo, Italy. Tel.: +39 3357012783; fax: +39 057527056.

E-mail address: [enzo.palminteri@inwind.it](mailto:enzo.palminteri@inwind.it) (E. Palminteri).



plus ventral) graft urethroplasty; VCUG, voiding cysto-urethrography

86.3% for the DGU, VGU and DVGU, respectively. There were no statistically significant differences among the three groups. Success rates decreased significantly only with a stricture length of > 4 cm.

**Conclusions:** In BM graft bulbar urethroplasties the ventral urethrotomy access is simple and versatile, allowing an intraoperative choice of dorsal, ventral or combined dorsal and ventral grafting, with comparable success rates.

© 2012 Arab Association of Urology. Production and hosting by Elsevier B.V. All rights reserved.

## Introduction

Buccal mucosa (BM) is considered the reference standard urethral substitute in graft bulbar urethroplasties, and its dorsal or ventral placement using the dorsal or ventral urethrotomy approaches has become a contentious issue, with no resolution to date [1,2].

In 1953, Presman and Greenfield [3] introduced ventral grafting by a ventral urethrotomy, which gives easy access to the urethra and good visualisation of the stricture. In 1996, this technique was revived by Morey and McAninch [4].

In 1996, Barbagli et al. [5] introduced the novelty of dorsal grafting by a dorsal urethrotomy. Nevertheless, the same authors recognised that the dorsal approach is simpler in the distal bulbar urethra, whereas the ventral approach with ventral grafting is more effective in the proximal bulbar urethra, where the spongiosum tissue is thick [6]. Also they advised that dorsal access might damage erectile function and the bulbar arteries

when the dissection from the corpora needs to be very proximal [6,7]. The dorsal urethral mobilisation was shown to be difficult in scarred urethras with marked periurethral fibrosis after previous treatments [8]; even an extensive dorsal approach could cause urethral ischaemia. Therefore, in 2001, Asopa et al. [8] described a different dorsal graft using a ventral urethrotomy approach, stating that the procedure is easier because the urethra is not mobilised. Recently, Kulkarni et al. [9] elaborated a modified dorso-lateral approach which preserves one lateral vascular supply to the urethra. In 2008, we described, for the first time, the combined dorsal plus ventral double graft for repairing very tight bulbar strictures [10].

To investigate the feasibility, efficacy and versatility of the ventral approach, in the present study we retrospectively evaluated and statistically analysed outcomes in 216 patients who underwent graft bulbar urethroplasty using a ventral urethrotomy access, and with the BM placed on the dorsal, ventral or dorsal plus

**Table 1** Patients and stricture characteristics in the three study groups.

Variable	DGU	VGU	DVGU
No. patients	32	121	63
Age (years), Mean $\pm$ (SD)	39.2 (16.2)	39.2 (13.3)	39.0 (14.3)
<i>Cause of stricture, n</i>			
Unknown	19	83	41
Catheter	6	27	17
Instrumentation	4	8	2
Trauma	3	3	2
Infection	0	0	1
<i>Previous treatment, n (%)<sup>*</sup></i>			
Dilatations	23 (71.9)	84 (69.4)	43 (68.2)
Urethrotomy	20	26	16
Urethroplasty	19	80	42
Urethroplasty	4	10	2
None	9	37	20
<i>Mean (SD)</i>			
Stricture length (cm)	3.2 (1.1)	3.7 (1.2)	3.4 (1.4)
Range	1.5–5	1.5–8	1.5–10
<i>Stricture length (cm), n</i>			
1.5–2	10	11	9
> 2–4	17	85	48
> 4–6	5	21	4
> 6	0	4	2
Median (range) follow-up (months)	43 (12–107)	27 (12–113)	49 (12–85)

<sup>\*</sup> One patient may receive more than one treatment.

ventral surface of the urethra. We also analysed the risk factors that could affect the success rate over a median follow-up of 37 months, using both bivariable and multivariable analyses.

## Patients and methods

### Patients

We reviewed the charts of patients with bulbar urethral strictures who underwent BM graft bulbar urethroplasty by a ventral-sagittal urethrotomy approach. The study included 216 consecutive patients who were treated between 1999 and 2008 and had completed a minimum follow-up of 12 months. None of the patients was lost to follow-up. Patients with lichen sclerosis and failed hypospadias repair were excluded. The study population was divided into three groups according to the location of the BM graft: dorsal, ventral or combined dorsal and ventral.

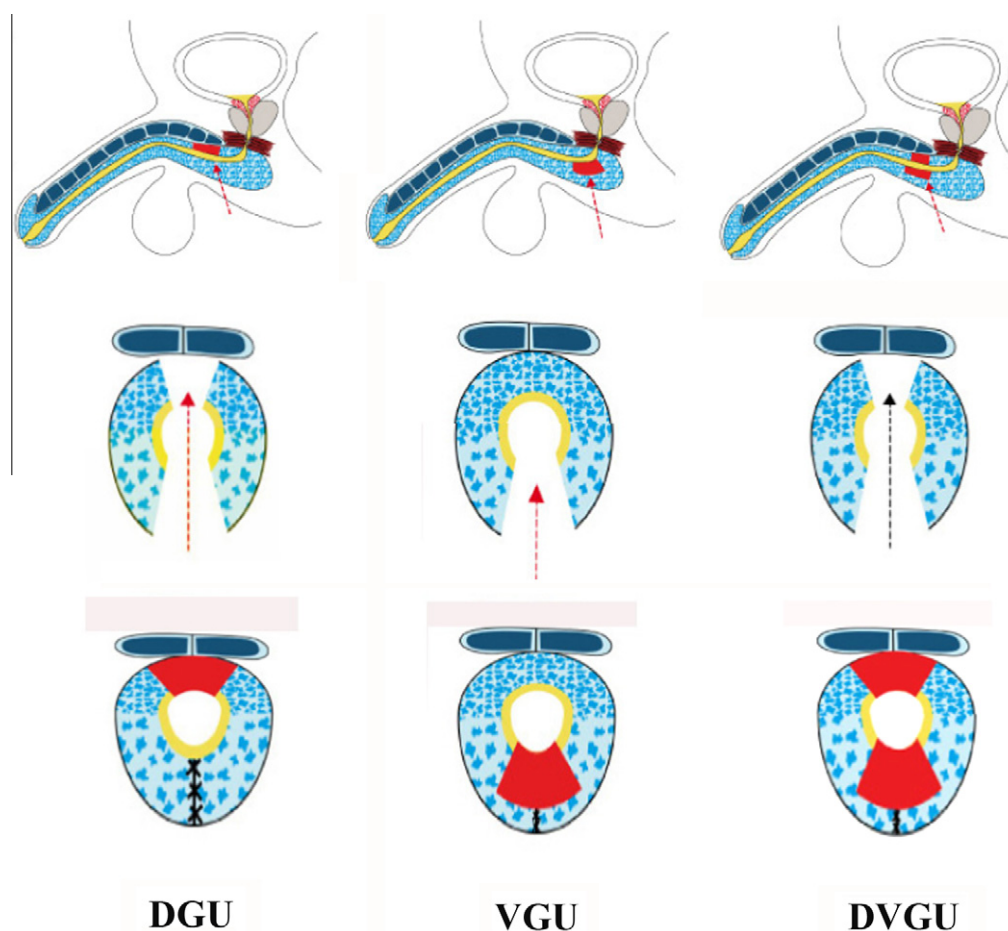
The techniques were selected according to the site and length of the stricture within the bulbar urethra, and according to the quality of the urethral plate. Generally, we used the dorsal graft in strictures located in the distal or middle bulbar urethra where, after incising the ure-

thral plate, it is easy to expose the corpora. A ventral graft was preferred in strictures located in the proximal bulbar urethra where it is difficult to work dorsally and the split of the corpora causes a lack of adequate support for the graft; furthermore, the abundant ventral spongiosum provides adequate vascularisation and support for the graft [4]. Finally, the dorsal plus ventral double graft was used in tight strictures with a narrow residual urethral plate (< 5 mm) in which a single patch seemed to be insufficient to make a sufficiently wide lumen.

Baseline patient and stricture characteristics are shown in Table 1. The preoperative evaluation included a clinical history, physical examination, oral cavity examination, urine culture, uroflowmetry, retrograde and voiding cysto-urethrography (VCUG) and urethroscopy. All patients were informed of the rare post-operative complications at the oral donor site.

### Surgical technique

All surgical procedures were carried out by the same urologist (E.P.). Through an inverted-Y incision the bulbocavernous muscles were divided, exposing the bulbar urethra. The strictured tract was opened by the



**Figure 1** Diagram illustrating DGU, VGU, and DVGU, using a ventral-sagittal urethrotomy approach.

ventral-sagittal urethrotomy approach, exposing the urethral plate, and then the BM patch graft was inserted dorsally, ventrally or dorsally ventrally to augment the urethra (Fig. 1). Of 216 urethroplasties, the graft was placed on the dorsal urethral surface using the technique of Asopa et al. in 32 (14.8%) cases, on the ventral surface in 121 (56%) and on the dorsal plus ventral surface by our previously described technique [10] in 63 (29.2%).

#### Dorsal graft urethroplasty (DGU)

The exposed dorsal urethral plate was incised in the midline down to the tunica albuginea. The margins of the incised dorsal urethra were dissected from the tunica without lifting the two halves of the bisected urethra. An elliptical raw area was created over the tunica where the graft was placed and sutured. A catheter was inserted and the lateral margins of the augmented urethral plate were sutured together with a running suture. Finally the adventitia of the spongiosum was closed [8].

#### Ventral graft urethroplasty (VGU)

The graft was sutured to the mucosal margins of the exposed dorsal urethral plate. A few stitches fixed the ventral spongiosum to the graft. Finally the adventitia of the spongiosum was closed over the graft [4,11].

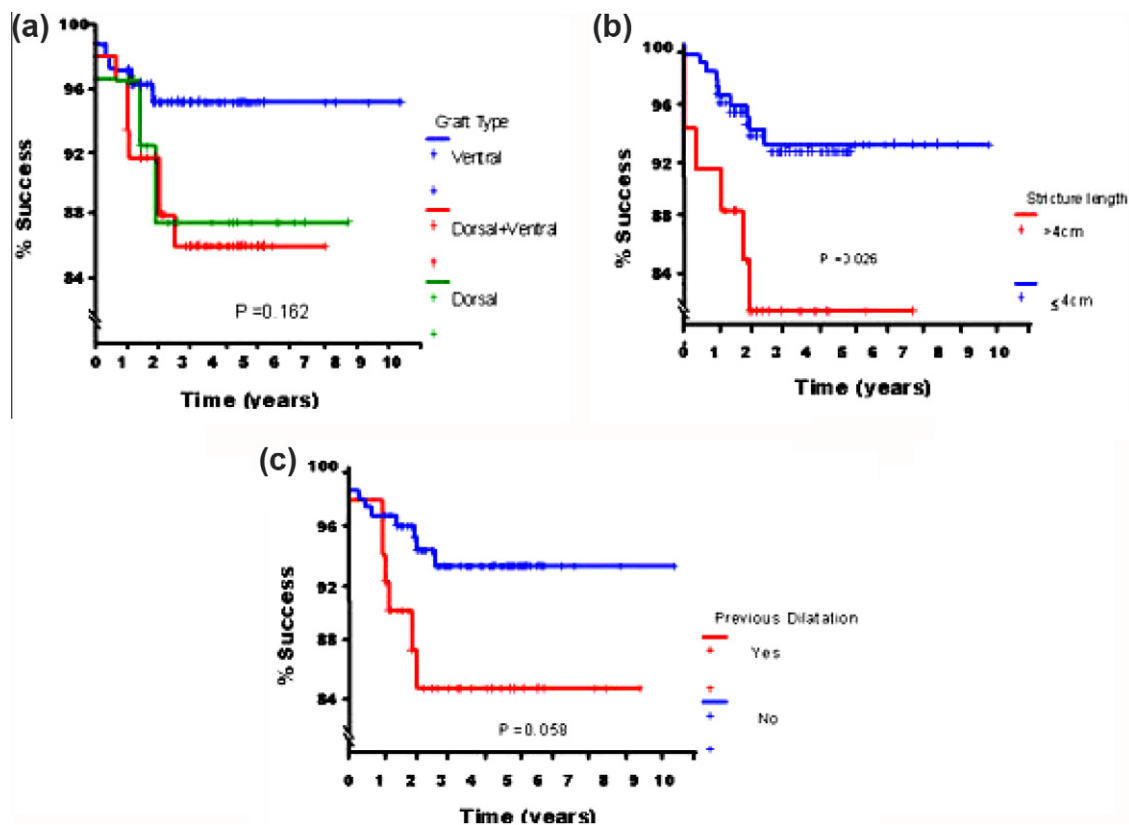
#### Dorsal plus ventral graft urethroplasty (DVGU)

The exposed dorsal urethral plate was incised in the midline to create an elliptical area where the first dorsal-inlay graft was placed to augment the urethra dorsally. Subsequently, the second ventral-onlay graft was sutured to the lateral urethral margins to complete ventrally the augmented urethroplasty by preserving the urethral plate. Finally, the spongiosum was closed over the graft [10].

#### Harvesting of BM

The BM was harvested from the cheek. Of 153 DGUs and VGUs, the BM was harvested from the right cheek in 152 patients and from both cheeks in one. Of 63 DVGUs, 58 patients had a wide single graft harvested from one cheek and subsequently tailored into two smaller grafts, according to the length of the dorsal and ventral urethral openings, while in four patients the two grafts were harvested bilaterally from both cheeks. The mean (SD, range) length of the harvested BM graft was 6 (0.36, 5–8) cm and the width was 1.7 (0.38, 1–2.5) cm.

A suction drain was left in place for 2 days. An 18-F Foley catheter was left in place for 3 weeks. Patients were usually discharged from the hospital 3 days after surgery and underwent VCUG 3 weeks later.



**Figure 2** Kaplan–Meier curves showing the correlation between success rate and (a) graft type, (b) stricture length, and (c) history of urethral dilatation before surgery.

### Follow-up

The follow-up assessment included recording any complaints after urethroplasty (urinary, genital and ejaculatory) by a simple clinical interview, uroflowmetry and urine culture every 4 months in the first year and annually thereafter. Whenever obstructive symptoms developed or the peak urinary flow rate deteriorated to < 14 mL/s, urethrography and urethroscopy were performed. Successful reconstruction was defined as normal voiding with no need for any postoperative procedure, including dilatation [4,6,10]. All patients were followed up for at least 12 months, the mean (SD, range) being 37 (19.8, 12–113) months.

### Statistical analysis

Data are presented as the mean (SD) or median, and groups were compared using the chi-square and Student's *t*-tests. The 5-year actuarial success rates were estimated by Kaplan–Meier curves and differences between groups were calculated using the log-rank test. Risk factors were assessed by calculating the odds ratio using bivariable analyses. To study the independent effect of prognostic factors on estimates of success rate, only at least borderline significant variables were entered into a multivariable analysis with a Cox proportional-hazards model. Statistical significance was considered to be indicated at  $P < 0.05$ . The study was approved by the local ethics committee.

### Results

In 11 (5%) cases, at VCUG after catheter removal, there was a fistula that resolved spontaneously with insertion of a 12-F catheter for two additional weeks; two cases were in the DGU group, five in the VGU group, and four in the DVGU group. Two patients had a perineal haematoma that was drained on the third day after surgery.

The overall 5-year actuarial success rate of the whole series was 91.4%. The 5-year actuarial success rates were 87.8%, 95.5% and 86.3% for the DGU, VGU and DVGU groups, respectively. There were no statistically significant differences among the groups (Fig. 2a,  $P = 0.162$ ). The stricture length had a significant effect on the 5-year actuarial success rate, with strictures of  $\leq 4$  cm having a better prognosis (Fig. 2b  $P = 0.026$ ). Patients with no history of urethral dilatation before treatment had a better 5-year actuarial success rate, that was almost significant (Fig. 2c,  $P = 0.058$ ). However, patient age, previous urethrotomy and previous urethroplasties had no statistically significant ( $P > 0.05$ ) effect on the 5-year actuarial success rate (Table 2).

Significant and borderline significant variables on bivariable analyses were entered into a multivariable Cox proportional-hazard model. Stricture length was

**Table 2** The 5-year actuarial success rate in the study groups.

Variable	<i>n</i> cases	Success rate (%)	<i>P</i> *
All	216	91.4	
Graft type			
Dorsal	32	87.8	
Ventral	121	95.5	
Dorsal + ventral	63	86.3	0.162
Age (years)			
< 50	167	90.4	
$\geq 50$	49	94.8	0.336
Length of stricture (cm)			
$\leq 4$	180	93.3	
> 4	36	82.3	0.026
Previous urethrotomy			
None	75	92.1	
1	59	89.4	
> 1	82	92.1	0.915
Previous dilatation			
No	154	93.4	
Yes	62	84.9	0.058
Previous urethroplasties			
No	200	91.2	
Yes	16	93.8	0.958

\*  $P < 0.05$  was considered significant.

the only independent factor that retained statistical significance on the multivariable analysis. The odds of failure among cases with a stricture length of > 4 cm were three times more than those with a length of  $\leq 4$  cm, with a 95% CI of 1.09–8.22.

Among successful cases, there was a marked improvement in peak urinary flow rate from a mean (range) preoperative value of 8.64 (2–15) mL/s to a mean postoperative value of 28.5 (14–49.6) mL/s at the last follow-up ( $P < 0.001$ ).

Sexual complaints were not reported by any of the patients. Of 16 failures, three were in the DGU group, five in the VGU group and eight in the DVGU group. Ten patients developed a short re-stricture at the distal or proximal site of the reconstruction; they were treated with one internal urethrotomy in nine cases and with two urethrotomies in one case. In six patients the re-stricture involved the entire grafted area; they were treated with perineostomy and are currently waiting for a staged solution.

### Discussion

In our experience, using the ventral approach, the ventral, dorsal and dorsal–ventral grafting techniques showed good 5-year actuarial success rates (95.5%, 87.8% and 86.3%, respectively). Our VGUs had a success rate (95.5%) similar to the 90–91.4% reported by others [11,12]. Our DGUs by a ventral urethral approach had a success rate (87.8%) similar to that of

dorsal graft techniques by a dorsal urethrotomy approach (90–98%), as reported by others using a similar follow-up interval [2].

However, even though many surgeons prefer to use the popular dorsal approach, recent overviews have confirmed that ventral or dorsal graft procedures have a similar success rate [13,14]. Thus, larger prospective randomised studies with a longer follow-up will be needed to analyse differences in outcome between the approaches.

Our success rate (90%) for graft urethroplasties for strictures of 1.5–2 cm was comparable with success rates (87–96%) reported in different series of anastomotic urethroplasty (AU) [12,15]. Al-Qudah and Santucci [16] suggested that AU is controversial for treating urethral strictures of 0.5–3 cm. They presented a series of short strictures treated with AU or BM graft and compared the results; the recurrence rate was 7% in the AU group and 0% in the BM group; sexual complications occurred in 18% of the patients after AU. In the present series, none of the patients reported sexual dysfunction. Nevertheless, similar to other investigators [17], we did not use a validated questionnaire for a rigorous assessment of sexual function. Thus, a larger series with a longer follow-up and adapted questionnaires will be needed to clarify whether, for short non-obliterating bulbar strictures, graft techniques could represent an alternative to the traditional AU, which is supported by the current evidence as the method of choice.

Traditionally, the older ventral urethrotomy has been considered an easy access to the urethral lumen, and which gives a good visualisation of the strictured tract [3,4,11]. As there is no mobilisation-rotation of the urethra, it is very simple to perform, particularly for reconstructive urologists under training with insufficient experience.

The better visualisation of the urethral plate by the ventral opening can allow any of the three solutions, i.e. dorsal, ventral, or dorsal plus ventral graft augmentation. The choice of graft placement is conditioned by the site of the stricture within the bulbar urethra and by the characteristics of the urethral plate. Generally, we used the dorsal graft in strictures in the distal or middle bulbar urethra, where the corpora represent a valid support for the graft. In the proximal bulbar urethra the split corpora precludes this support; furthermore, the difficulty of working dorsally in the deep bulb, and the substantial ventral spongiosum encourage ventral grafting [6]. In tight strictures with a very narrow urethral plate, in which a single patch seemed to be insufficient to reconstruct an adequate lumen, we preferred the dorsal plus ventral double grafting. Also, Elliot et al. [11] stated that in the presence of a very narrow urethral plate, the standard ventral augmentation could be inadequate, suggesting the use of a 2.5-mm wider graft.

In 2008, we introduced the use of DVGU, postulating some advantages [10]. Avoiding a wide single ventral

graft, double grafting might decrease the chance of fistulae and diverticula. The dorsal augmentation is rather small, due to the difficulty of mobilisation of the urethral plate that the ventral approach entails. Thus, the additional second graft could correct the initial use of a single dorsal graft that was later judged to be insufficient for an adequate augmentation. Avoiding a complete section of the spongiosum, the DVGU preserves the urethral plate and urethral vascularity [10,18]. The aim was to maintain the urethral axial integrity and the original urethral length, reducing the hypothetical sexual complications related to the AU [16,19–22]. Abouassaly and Angermeier [18] advised against the use of the AU in cases with distal urethral disease, in which the urethral transection would further compromise the blood supply. Furthermore, they stated that, following the urethral transection, the stricture could be longer than that seen on urethrography, and it could cause difficulty in making the AU, with an increased risk of complications. Conversely, the ventral urethral opening allows the surgeon to choose an adequate solution after evaluating the stricture and its length [18].

In the present study we reviewed our results according to the factors that can potentially influence the success rate of the urethroplasties. Stricture aetiology, patient age, and previous urethrotomy or urethroplasty had no statistically significant effect on the results, whilst the success rate decreased with stricture lengths of > 4 cm.

The main weakness of the present study is that it was retrospective and not prospective. The population could not be considered homogeneous for the number of patients, stricture aetiology and characteristics, patient's characteristics, and surgeon's preference. This could bias the statistical analysis. Nevertheless, our study showed clearly that a BM graft through a ventral urethrotomy access is a versatile technique that could be used for dorsal, ventral or combined dorsal and ventral grafting, with comparable success rates.

In conclusion, in graft bulbar urethroplasties, the ventral urethrotomy approach appears to be simple and versatile because it allows a better visualisation of the urethral plate, and it permits any of the three different solutions, i.e. dorsal, ventral, or dorsal plus ventral graft augmentation. The dorsal or ventral grafting is used according to the stricture characteristics and site within the bulbar urethra. The double dorsal plus ventral graft is useful in tight strictures in which a single graft augmentation is insufficient. Using the ventral approach, all three grafting techniques had a comparable success rate, which decreased with the increase of stricture length.

#### **Conflict of interest**

No conflict of interest to declare.

## References

- [1] Andrich DE, Mundy AR. What is the best technique for urethroplasty? *Eur Urol* 2008;**54**:1031–41.
- [2] Patterson JM, Chapple CR. Surgical techniques in substitution urethroplasty using buccal mucosa for the treatment of anterior urethral strictures. *Eur Urol* 2008;**53**:1162–71.
- [3] Presman D, Greenfield DL. Reconstruction of the perineal urethra with a free full-thickness skin graft of the prepuce. *J Urol* 1953;**69**:677–80.
- [4] Morey AF, McAninch JW. When and how to use buccal mucosal grafts in adult bulbar urethroplasty. *Urology* 1996;**48**:194–8.
- [5] Barbagli G, Selli C, Tosto A, Palminteri E. Dorsal free graft urethroplasty. *J Urol* 1996;**155**:123–6.
- [6] Barbagli G, Palminteri E, Guazzoni G, Montorsi F, Turini D, Lazzeri M. Bulbar urethroplasty using buccal mucosa grafts placed on the ventral, dorsal or lateral surface of the urethra: are results affected by the surgical technique? *J Urol* 2005;**174**:955–8.
- [7] Iselin CE, Webster GD. Dorsal onlay graft urethroplasty for repair of bulbar urethral stricture. *J Urol* 1999;**161**:815–8.
- [8] Asopa H, Garg M, Singhal GG, Singh L, Asopa J, Nischal A. Dorsal free graft urethroplasty for urethral stricture by ventral sagittal urethrotomy approach. *Urology* 2001;**58**:657–9.
- [9] Kulkarni S, Barbagli G, Sansalone S, Lazzeri M. One-sided anterior urethroplasty: a new dorsal onlay graft technique. *BJU Int* 2009;**104**:1150–5.
- [10] Palminteri E, Manzoni G, Berdondini E, Di Fiore F, Testa G, Poluzzi M, et al. Combined dorsal plus ventral double buccal mucosa graft in bulbar urethral reconstruction. *Eur Urol* 2008;**53**:81–90.
- [11] Elliot SP, Metro MJ, McAninch JW. Long-term followup of the ventrally placed buccal mucosa onlay graft in bulbar urethral reconstruction. *J Urol* 2003;**169**:1754–7.
- [12] Barbagli G, Guazzoni G, Lazzeri M. One-stage bulbar urethroplasty. Retrospective analysis of the results in 375 patients. *Eur Urol* 2008;**53**:828–33.
- [13] Wang K, Miao X, Wang L. Dorsal versus ventral onlay urethroplasty for anterior urethral stricture: a meta-analysis. *Urol Int* 2009;**83**:342–8.
- [14] Barbagli G, Lizzari M. Surgical treatment of anterior urethral stricture diseases: brief overview. *Int Braz J Urol* 2007;**33**:461–9.
- [15] Santucci RA, Mario LA, McAninch JW. Anastomotic urethroplasty for bulbar urethral stricture. Analysis of 168 patients. *J Urol* 2002;**167**:1715–9.
- [16] Al-Qudah HS, Santucci RA. Buccal mucosal onlay urethroplasty versus anastomotic urethroplasty (AU) for short urethral strictures: which is better? *J Urol (Suppl)* 2006;**175**:103 [(Abstract) 313].
- [17] O'Riordan A, Narahari R, Kumar V, Pickard R. Outcome of dorsal buccal graft urethroplasty for recurrent bulbar urethral strictures. *BJU Int* 2008;**102**:1148–51.
- [18] Abouassaly R, Angermeier KW. Augmented anastomotic urethroplasty. *J Urol* 2007;**177**:2211–6.
- [19] Guralnick ML, Webster GD. The augmented anastomotic urethroplasty. Indications and outcome in 29 patients. *J Urol* 2001;**165**:1496–501.
- [20] Morey AF, Kizer WS. Proximal bulbar urethroplasty via extended anastomotic approach – what are the limits? *J Urol* 2006;**175**:2145–9.
- [21] Barbagli G, De Angelis M, Romano G, Lazzeri M. Long-term followup of bulbar end-to-end anastomosis: a retrospective analysis of 153 patients in a single center experience. *J Urol* 2007;**178**:2470–3.
- [22] Mundy AR. Results and complications of urethroplasty and its future. *Br J Urol* 1993;**71**:322–5.