



## **The Effect of Ethanolic Extract of *Tridax procumbens* on Potassium Bromate Induced Toxicity in the Kidney of Wistar Rats**

**J. K. Opara<sup>1\*</sup>, F. C. Akpuaka<sup>2</sup> and G. U. Ndukwe<sup>2</sup>**

<sup>1</sup>Department of Anatomy, College of Medicine and Health Science, Gregory University, Uturu, Nigeria.

<sup>2</sup>Department of Anatomy, College of Medicine and Health Science, Abia State University, Uturu, Nigeria.

### **Authors' contributions**

*This work was carried out in collaboration between all authors. Author JKO designed the study, performed the statistical analysis and wrote the protocol. Author GUN monitored the first draft of the manuscript. Author FCA supervised the entire process and author JKO performed the bench work. All authors read and approved the final manuscript.*

### **Article Information**

DOI: 10.9734/AJRIMPS/2018/46121

#### Editor(s):

- (1) Dr. S. Prabhu, Department of Biotechnology, Sri Venkateswara College of Engineering, Sriperumbudur, India.  
(2) Dr. Somdet Srichairatanakool, Professor, Department of Biochemistry, Faculty of Medicine, Chiang Mai University, Chiang Mai 50200, Thailand.

#### Reviewers:

- (1) Erhirhie Earnest Oghenesuvwe, Nnamdi Azikiwe University, Nigeria.  
(2) Veeravan Lekskulchai, Srinakharinwirot University, Thailand.  
(3) P. Ramachandra Reddy, Yogi Vemana University, India.

Complete Peer review History: <http://www.sdiarticle3.com/review-history/46121>

**Original Research Article**

**Received 19 October 2018**  
**Accepted 27 December 2018**  
**Published 18 January 2019**

### **ABSTRACT**

**Aim:** To investigate the histological effect of ethanolic extract of *Tridax procumbens* leaf commonly used as medicinal plant, on potassium bromate induced nephrotoxicity in adult Wistar rats.

**Place and Duration of Study:** Department of Anatomy, Faculty of Basic Medical Sciences, Abia State University, Uturu Nigeria /within three months.

**Methodology:** Twenty adult wistar rats weighing between 160 – 180 g were divided into four groups of five rats each. Group A served as the control and received distilled water only for 14 days, Group B received 100 mg/kg of potassium bromate only for 14 days, Group C received 300 mg/kg of *T. procumbens* leaf extract only for 14 days and Group D received 100 mg/kg of potassium bromate + 300 mg/kg of *T. procumbens* leaf extract simultaneously for 14 days. Twenty

\*Corresponding author: E-mail: [oparajulia@gmail.com](mailto:oparajulia@gmail.com);

four hours after the last administration, the animals were weighed, anaesthetized and sacrificed. The kidneys were harvested and weighed. Statistical analysis using one way ANOVA and Dunnett's post hoc test was done for all parameters measured. The significance was set at  $P < 0.05$ . **Results:** There was significant decrease in mean body weight of group B animals ( $178.0 \pm 4.55$  to  $162.3 \pm 2.59$ ) and significant increase in kidney weight of group B animals ( $0.75 \pm 0.02$ ) when compared to the control and other treated groups. Extract of *T. procumbens* inhibited potassium bromate induced weight loss and increase in kidney weight. Histologically, there was no significant pathology of the kidney tissue after treatment with *T. procumbens*. **Conclusion:** From this study, it can be deduced that ethanolic extract of *T. procumbens* leaf produced significant protective effect against potassium bromate induced toxicity in the kidney of Wistar rats.

**Keywords:** *Tridax procumbens*; toxicity; potassium bromate and kidney; wistar rats.

## 1. INTRODUCTION

Potassium bromate ( $\text{KBrO}_3$ ) is an oxidizing agent that exists as a white crystal powder. It has been used as a food additive mainly in the making of bread and as dough conditioner [1]. Potassium bromate has been found to be generated as a contaminant in drinking water; this is due to the conversion of bromide found naturally in water to bromate by ozone which is used as disinfectant [2,3]. Toxicity studies have shown the dangers potassium bromate poses to health if consumed in water or food, with previous reports documenting the induction of multiple organ toxicity in humans and experimental animals [4,5]. Furthermore, researchers found potassium bromate to have the potential of inducing cancer, liver failure, kidney failure, deafness, pains, redness of the eye and skin [6,7]. This led to the ban of potassium bromate as food additives in several developed and developing countries [8]. Despite its ban, some developing countries still make use of potassium bromate as flour enhancer.

Plant derived products have been used for medicinal purposes for centuries and presently, it is estimated that about 80% of the world population relies on botanical preparations as medicines to meet their health needs [9]. This may be attributable to the down turn in the economy, as herbal medicine is perceived to be a cheaper means of treatment [10]. *Tridax procumbens* Linn (Family Asteraceae) is specie of flowering plant in the daisy family. Its common names include "coat button" and "Tridax daisy" in English, "cadillo chisaca" in Spanish, "herbe caille" in French, "jayanti veda" in Sanskrit, "Ghamra" in Hindi, "Doyadi" in Marathi, "Thata poodi" in tamil, "Kotobukigiku" in chinese, "Bishalya Karani" in Oriya, "Chiravanak" in malayalam and "mbuli" in Ibo [11]. *Tridax*

*procumbens* is native to Central America and tropical South America, but has spread throughout the tropical and subtropical parts of the world [12]. Extract of this plant has been found to possess significant medicinal properties against blood pressure, bronchial catarrh, malaria, dysentery, diarrhoea, stomach ache, headache and wounds [13]. In addition, the plant has also shown various pharmacological activities like Immunomodulatory, Antidiabetic, Antihepatotoxic and Anti-oxidant, Anti-inflammatory, Analgesic, and marked depressant action on respiration [14-18].

Most organ function impairment is a direct consequence of changes in the histological structures of the organ. *T. procumbens* have been reported to have protective effect against toxicity of the liver [19]; however, there is limited information on its effect on toxicity of the kidney. Hence, this study therefore investigates the effect of *T. procumbens* on potassium bromate induced toxicity in the kidney.

## 2. MATERIALS AND METHODS

### 2.1 Animals

Twenty (20) healthy adult Wistar rats weighing between 160-180g were procured from the animal house of Abia State University, Uturu. They were kept in standard cages under normal temperature ( $27-30^\circ\text{C}$ ) and were fed with Guinea feeds (pelletized) and water *ad libitum*. The animals were acclimatized for a period of two weeks before treatment. The ethical committee of the College for animal care and use, Abia State University, Uturu approved the study design in compliance with the National regulation for animal research.

## 2.2 Collection and Preparation of Plant Material

Fresh leaves of *Tridax procumbens* were obtained from Uturu, Abia State and were identified by the Herbarium officer of Botany department, Abia State University, Uturu. The leaves were rinsed in a basin of water to remove sand and debris, put in a sieve to drip off water and then dried at 40°C in a thermostatically controlled oven. The dried leaves were crushed into fine powder using a laboratory blender and extraction was done using ethanol. The coarse powder was soaked in ethanol for forty eight (48) hours and then filtered into a beaker with a white cloth. The filtrate was concentrated using a rotary evaporator and further dried using laboratory oven into a jelly-like form and stored in refrigerator for future use. The stock solution of the extract was prepared by dissolving 1 g of the extract in 10 ml of distilled water.

Potassium bromate was procured from the Department of Biochemistry, Abia State University, Uturu. 1 g of potassium bromate was dissolved in 20 ml of distilled to give a concentration of 50 mg/ml.

## 2.3 Experimental Protocol

The twenty adult Wistar rats were weighed and randomly allocated into four (4) groups of five animals each, designated as groups A, B, C and D.

Group A served as the control group and received 2 ml/kg of distilled water only

Group B received 100 mg/kg of potassium bromate only for 14 days

Group C received 300 mg/kg of *T. procumbens* leaf extract only for 14 days

Group D received 100 mg/kg of potassium bromate + 300 mg/kg of *T. procumbens* leaf extract simultaneously for 14 days.

The extracts were administered orally once daily between the hours of 10-11 am and lasted for a

period of fourteen (14) days. Twenty four hours after the last administration, the animals were weighed, anaesthetized by chloroform inhalation and dissected. The kidneys were harvested, weighed and fixed in 10% formal saline for histological examination.

## 2.4 Tissue Processing

The kidney tissues were passed through the processes fixation, dehydration, clearing, infiltration, embedding, sectioning and staining. The tissues were fixed in 10% formal saline, followed by dehydration with graded percentages of alcohol (50%, 70%, 90% and absolute alcohol). After dehydration, the tissues were then cleared in xylene after which it was embedded in paraffin wax. Rotatory microtome was used to obtain tissue sections of 3-5 µm thick. The sections were deparaffinised, hydrated and stained using Haematoxylin and Eosin (H&E) dye. The slides were later viewed under the light microscope and the images captured.

## 2.5 Statistical Analysis

Data was analysed using Statistical Package for Social Sciences (SPSS) software version 16 (Chicago IL) and results were presented as Mean ± standard error of mean (SEM). One way Analysis of Variance (ANOVA; 95% confidence interval) was used to determine the significance of difference in the means of all parameters. Dunnett post-hoc multiple comparison procedure was done for comparisons between treated groups and control.

## 3. RESULTS

### 3.1 Body Weight Changes

Table 1 shows the mean body weight changes in groups A, B, C and D respectively. There was significant ( $P = .003$ ) loss of body weight in group B compared to the control.

**Table 1. Mean ± SEM of initial mean body weight, final mean body weight and mean weight gain in all the groups (A, B, C and D)**

Groups	Initial body weight	Final body weight	Weight gain
A	161.8±9.91	177.3±11.15	15.5±3.01
B	178.0±4.55	162.3±2.59	-15.8±2.95*
C	163.5±5.81	179.8±7.55	16.25±8.98
D	162.3±7.48	175.5±5.91	13.25±3.92

\*significant compared to control

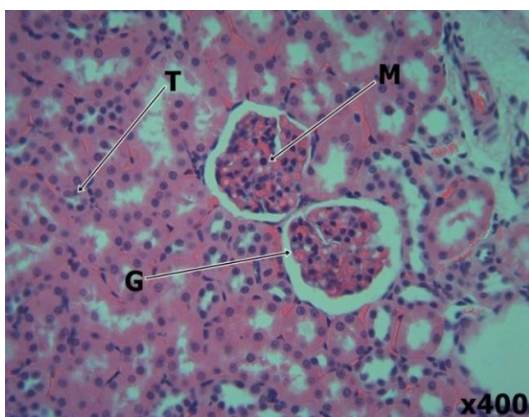


Plate 1. (Control)

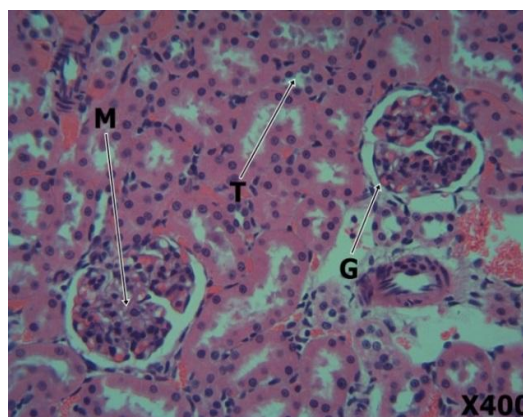


Plate 2. (Potassium bromate 100 mg/kg)

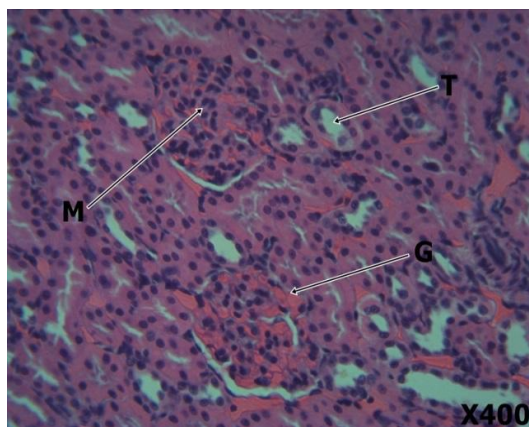


Plate 3. (*Tridax procumbens* 300 mg/kg)

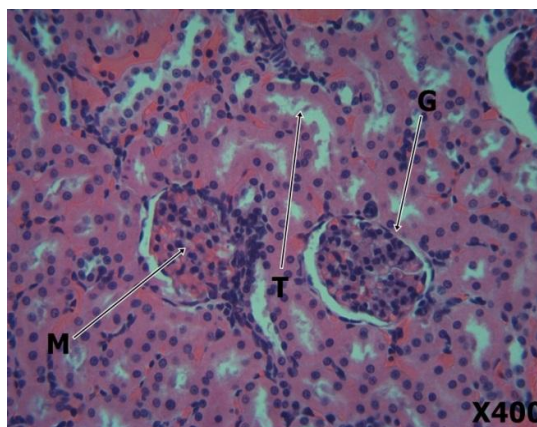


Plate 4. (potassium bromate 100 mg/kg + *T. procumbens* 300 mg/kg)

**Fig. 1. Plates 1-4 shows the photomicrograph of kidney tissues of the treated rats**  
 Plate 1 is the kidney tissue of rats given distilled water showing normal features of the kidney such as glomeruli (G), renal tubules (T) and mesangium (M). Plate 2 is the kidney tissue of rats treated with 100 mg/kg body weight of potassium bromate only showing severe distortion of renal architecture with focal tubular necrosis, severe haemorrhage in the interstitium and focal loss of glomeruli. Plate 3 is the kidney tissue of rats treated with 300 mg/kg body weight of ethanolic extract of *T. procumbens* only showing mild congestion of the glomerulus, normal tubules and mesangium. Plate 4 is the kidney tissue of rats treated with 100 mg/kg of potassium bromate and 300 mg/kg of extract of *T. procumbens* showing moderate restoration of renal architecture to normal with healthy glomerulus, well perfused tubular tissue and normal mesangium. However, there is mild haemorrhage in the interstitium of some areas.

### 3.2 Kidney Weights

There was significant increase ( $P = .04$ ) in the relative kidney weight in group B compared to the control and other experimental groups (Table 2). The extract of *T. procumbens* showed no significant difference in the relative kidney weights of other groups when compared to the control.

### 3.3 Histological Findings

Photomicrographs from the control revealed that the kidney tissues of rats administered distilled water showed normal features of the kidney such as glomeruli (G), renal tubules (T) and mesangium (M). Kidney tissues of animals in group B showed severe distortion of renal architecture with focal tubular necrosis, severe haemorrhage in the interstitium and focal loss of glomeruli. Group C kidney tissues of rats treated

with 300 mg/kg body weight of ethanolic extract of *T. procumbens* only showed mild congestion of the glomerulus, normal tubules and mesangium. Group D treated with 100 mg/kg of potassium bromate and 300 mg/kg of extract of *T. procumbens* showed moderate restoration of renal architecture to normal with healthy glomerulus, well perfused tubular tissue and normal mesangium. However, there was mild haemorrhage in the interstitium of some areas.

#### 4. DISCUSSION

Medicinal plants contain numerous biologically active compounds that have shown to be useful in improving the life and treatment of diseases [20]. *T. procumbens* appear to be a very promising medicinal plant containing many active molecules evident by its vast medicinal and pharmacological properties [18].

There was statistically significant reduction in body weight of animals in group B when compared to the control. This could probably be as a result of loss of appetite by the animals in the group or due to prolonged exposure to toxicity. This is in agreement with the findings of Okalie and Ikewuchi [21] who reported a significant reduction in the body weights of rabbits that received potassium bromate. In contrast, Farombi et al. [4] and Watanabe et al. [22] reported the absence of the effect of potassium bromate on the body weight of the animals.

**Table 2. Effect of ethanolic extract of the leaf of *T. procumbens* on relative kidney weight of treated rats**

Groups	Kidney weights
A	0.59 ± 0.03
B	0.75 ± 0.02*
C	0.58 ± 0.08
D	0.59 ± 0.03
PROB. OF SIG.	<0.05

\*significant compared to control

The relative kidney weight showed a statistically significant increase in group B animals when compared to control group A. This however could be pathological as the kidney might have been inflamed due to toxicity. This is in support with previous works done by Farombi et al. [4] who reported relative liver and kidney weight increase in rats administered potassium bromate. The relative kidney weight of groups C and D were

similar to that of the control and it could be as a result of the antioxidant and anti-inflammatory properties present in the leaves of *T. procumbens* which are responsible for inhibiting inflammation.

The histopathological finding reveals that kidney tissues in group B showed cellular abnormality in the kidney with evidences of tubular necrosis. This may be due to the nephrotoxic effect of potassium bromate. This is in agreement with earlier studies by Akanji et al. [23] and El-Sokkary [24]. Group D showed normal kidney tissue architecture. This may be related to the importance of vitamin E as an antioxidant that scavenges free radicals curbing the damage mechanism of potassium bromate [25]. This is in conformity with previous research by Adeluwoye et al. [26] who showed that ethanolic extract of *T. procumbens* possesses some antioxidant effects.

#### 5. CONCLUSION

The ethanolic extract of *T. procumbens* leaf showed no significant pathology in the kidney tissues of the rats. This study clearly demonstrates that *T. procumbens* has the potential ability to protect against potassium bromate induced kidney toxicity in adult Wistar rats by acting as antioxidant. This study recommends the consumption of *T. procumbens* which could help ameliorate the effect of liver toxicity.

#### CONSENT

It is not applicable.

#### ETHICAL APPROVAL

The ethical committee of the College for animal care and use, Abia State University, Uturu approved the study design in compliance with the National regulation for animal research.

#### COMPETING INTERESTS

Authors have declared that no competing interests exist.

#### REFERENCES

1. Diachenko GW, Warner CR. Potassium bromate in bakery products. In LEE, TC. and HO, CT. (Eds.). Bioactive Compounds in Foods. Washington: American Chemical Society. 2002;218.

2. Ueno H, Oishi K, Sayato Y, Nakamuno K. Oxidative cell damage in kat-sod assay of oxyhalides as inorganic disinfection by-product and their occurrence by ozonation. Arch Environ Contam Toxicol. 2000; 38(1):1-6.
3. Cavangagh JE, Weinberg HS, Gold A, Sangalah R, Marburg D, Glase W. Ozonation Byproducts; Identification of bromohydrins from the ozonation of natural waters with enhanced bromide levels. Environ. Sci. Technol. 1992;26:1658-62.
4. Farombi EO, Alabi MC, Akuru TO. Kolaviron modulates cellular redox status and impairment of membrane protein activities induced by potassium bromate KBr O<sub>3</sub> in rats. Pharmacol Res. 2002;45:63-8.
5. Dimkpa U, Ukoha UU, Anyabolu EA, Uchefuna RC, Anikeh LC, Oji OJ, et al. Hepatotoxic effects of potassium bromate on adult wistar rats. Journal of Biology, Agriculture and Healthcare. 2013;3(7):111-115.
6. Mack RB. Round up the usual suspects; Potassium bromate poisoning. North Carolina Medical Journal. 1988;49:243-245.
7. DeAngelo AB, George MH, Kilburn SR, Moore TM, Wolf DC. Carcinogenicity of potassium bromate administered in the drinking water to male B6C3F mice and F344/N rats. Toxicologic Pathology. 1998; 26(5):587-594.
8. Ekop AS, Obot IB, Ikpatt EN. Anti-nutritional factors and potassium bromate content in bread and flour samples in UYO Metropolis. Niger. E-J. Chem. 2008;5(4):736-741.
9. Shri JNM. Ginger: It's role in xenobiotic metabolism. ICMR Bulletin. 2003;33(6):57-63.
10. Kamboj VP. Herbal medicine. Curr Sci. 2000;78:35-51.
11. Rahman AH, Alam MS, Khan SK, Ferdous A, Islam AK, Rahman MM. Taxonomic studies on the family Asteraceae (compositae) of the Rajshahi division. Research Journal of Agriculture and Biological Sciences. 2008;42:134-140.
12. Chauhan BS, Germination DE. Ecology of two troublesome asteraceae species of rainfed rice: Siam weed (*Chromolaena odorata*) and Coat buttons (*Tridax procumbens*). Johnson Weed Science. 2008;56:567-573.
13. Sahoo M, Chand PK. In vitro multiplication of a medicinal herb *Tridax procumbens* L. (Mexican Daisy, coat button): Influence of explanting season, growth regulator synergy, culture passage and planting substrate. Phytomorphology. 1998;48:195-206.
14. Ravikumar V, Shivashangari KS, Devaki T. Effect of *Tridax procumbens* on liver antioxidant defense system during lipopolysaccharid- induced in Dgalactosomine sensitized rats. Mol. Cell Biochem. 2005;269(1-2):131-6.
15. Vyas P, Suresh Tiwari U, Rastogi B, Singh P. Immunomodulatory effects of aqueous extract of *Tridax procumbens* in experimental animals. Journal of Ethnopharmacology. 2004;92:113-119.
16. Bhagwat DA, Killedar SG, Adnaik RS. Anti-diabetic activity of leaf extract of *Tridax procumbens*. International Journal of Green Pharmacy. 2008;2:126-8.
17. Reddipalli H. Anti-hepatotoxic and antioxidant defense potential of *Tridax procumbens*. Int. J. of Green Pharmacy. 2008;2(3):164-169.
18. Diwan PV, Iravati K, Margaret I, Sattur PB. Pharmacology and biochemical evaluation of *Tridax procumbens* on inflammation. Indian J of Pharmacology. 1989;21:1-7.
19. Sampathkumar P, Kalavathy S, Anand AV, Sangeetha T, Sujeetha P. Impact of *Tridax procumbens* on Heamatological parameters in aflatoxin induced liver toxicity in albino rats. Pharmacog. Journal. 2018;10(2):304-308.
20. Shivananda N. Influence of ethanol extract of *vinca rosea* on wound healing in diabetic rats. Online Journal of Biological Sciences. 2006;62:51-55.
21. Okalie NP, Ikewuchi JC. Cataractogenic potential of bromated mediated oxidative stress in rabbits. Journal Med. Sci. 2004;4:158-163.
22. Watanabe S, Tajima Y, Yamaguchi T, Fukui T. Potassium bromate induced hyper-uricemia stimulates acute kidney damage and oxidative stress. J. Health Sci. 2004;50:647-653.
23. Akanji MA, Nafiu MO, Yakubu MT. Enzyme activities and histopathology of selected tissues in rats treated with potassium bromate. African Journal of Biomedical Research. 2008;11:87-95.
24. El-Sokkary GH. Melatonin protects against oxidative stress induced by the kidney

- carcinogen potassium bromated. 26. Adeluwoye AO, Odunola OA, Gbadegesin MA, Adelabu OO. Assessment of the effect of ethanol extract of *Tridax procumbens* (Linn.) on sodium arsenite-induced toxicities in male wistar rats. Am. J. Biomed. Sci. 2017;9(3):151-165.
25. Ikwuchu JC, Ikwuchi CC, Igboh NM. Chemical profile of *Tridax procumbens* Linn. Pakistan Journal of Nutrition. 2009;8(5):548–550.

---

© 2018 Opara et al.; This is an Open Access article distributed under the terms of the Creative Commons Attribution License (<http://creativecommons.org/licenses/by/4.0>), which permits unrestricted use, distribution, and reproduction in any medium, provided the original work is properly cited.

*Peer-review history:*  
The peer review history for this paper can be accessed here:  
<http://www.sdiarticle3.com/review-history/46121>